



Case Series

Transforming pediatric dentistry with digital technology - the way ahead – A case series

Gaurav Gupta^{1*}, D.K Gupta², Priyanka Gupta³, Abhishek Khairwa⁴, Parth Shah⁵, Neeraj Chandra⁶

¹Dept. of Pediatric and Preventive Dentistry, Jaipur Dental College, Jaipur, Rajasthan, India

²Dept. of Pedodontics and Preventive Dentistry, Wisdom Dental Clinics, Jaipur, Rajasthan, India

³Dept. of Pedodontics and Preventive Dentistry, RUHSDS Govt. Dental College, Jaipur, Rajasthan, India

⁴Dept. of Pedodontics and Preventive Dentistry, Jaipur Dental College, Jaipur, Rajasthan, India

⁵Dept. of Pedodontics and Preventive Dentistry, Saachi Children Hospital, Surat, Gujarat, India

⁶Dept. of Pedodontics and Preventive Dentistry, Institute of Dental Sciences, Bareilly, Uttar Pradesh, India



ARTICLE INFO

Article history:

Received 05-05-2023

Accepted 30-06-2023

Available online 31-07-2023

Keywords:

CAD/CAM

Digital workflow

Paediatric

Space maintainer

ABSTRACT

With the rapid growth in digital technologies, there is always something new to learn and develop redefining the old. Not only in adults, but digital workflow plays a good role even in the paediatric field of dentistry. This workflow cuts down chair side time, thus shortening the procedure, and also improves children's cooperation. They seem to be potentially used in children due to their advantages like comfort, precision and time saviour. In the present report we encourage the use of digital technology in paediatric dentistry.

This is an Open Access (OA) journal, and articles are distributed under the terms of the [Creative Commons Attribution-NonCommercial 4.0 International](https://creativecommons.org/licenses/by-nc/4.0/), which allows others to remix, and build upon the work non-commercially, as long as appropriate credit is given and the new creations are licensed under the identical terms.

For reprints contact: reprint@ipinnovative.com

1. Introduction

The importance of maintaining primary dentition until its normal physiological exfoliation does not only preserve aesthetics, function, and speech but also aids in normal eruption and guidance of their permanent successor teeth.¹

If there is no enough arch length, it may likely lead to malocclusion such as crowding, ectopic eruption also tooth impaction.² Space maintainers (SM) help in preservation of present dentition displacement so as to avoid loss of arch length, width, and perimeter.³

The most common method of obtaining impressions for SM is alginate impressions with dental stone cast models but this method has the disadvantages of offending to distortion overtime as water evaporates thereby creating inaccuracies in impressions and stone casts.^{4,5}

A 2 year follow-up showed that the use of in office CAD/CAM technology on young patient gave satisfactory results, thus improving quality of life. Smile restoration, preservation of tooth structure, less clinical work, time preservation, improved patient compliance are all possible with digital workflow procedures.⁶

Current case report series describe the use of intraoral scanners in making digital impressions for fabrication of band and loop and distal shoe space maintainers. This method reduced chair side time in an uncooperative paediatric patient; increased practice efficiency with enhancements in patient compliance and comfort. Since impression could be an unpleasant experience for some children due to behavioural issues, gag reflex and time taking can be problematic; thus switching to digital procedures may have positive impact on child's perception of dental procedures eliminating the need of alginate impression.

* Corresponding author.

E-mail address: devanshisankhla@gmail.com (G. Gupta).

2. Case Report 1

A 5-year-old child reported to the dental clinic with chief complaint of pain in right lower back tooth region since last few months with non-contributory medical history. Upon intraoral examination, it was found that the patient had grossly decayed right lower first molar as when scanned with CEREC (Chairside Economical Restorations of aesthetic Ceramic) intraoral scanner. (Figure 1)

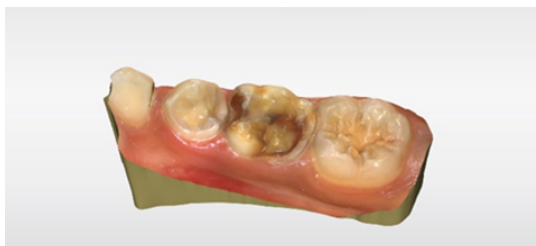

Figure 1: Digital scan using the CEREC Omnicam scanner

There was no scope of saving the tooth, so extraction was planned due to poor prognosis. After informing the parents extraction was carried out of the right lower first molar. Scanning was done immediately after extraction; these next generation intraoral scanners can even scan in presence of blood & saliva, they have inbuilt A.I. (artificial intelligence) driven soft tissue elimination technology. (Figure 2 a, b)

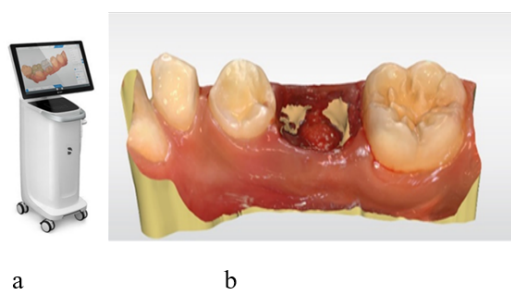


Figure 2: a: CEREC Omnicam scanner b: Digital scan of extracted tooth

Due to less space there was need for space maintainer (SM). So, decided to fabricate band and loop SM using the recent digital technology. As patient was non-cooperative in current case, digital impression is faster and also more comfortable for such pediatric patients.

Using the CEREC Omnicam scanner (Densply Sirona):

- Only desired side lower right arch impression was made
- Within 30 seconds
- Resulting file transferred to dental laboratory for 3Dmodel printing online (Figure 3)
- Normal protocol to fabricate a cast metal band and loop was followed. (Figure 4)
- After 5days the appliance was tried in, placement was confirmed, cementation with resin modified glass ionomer

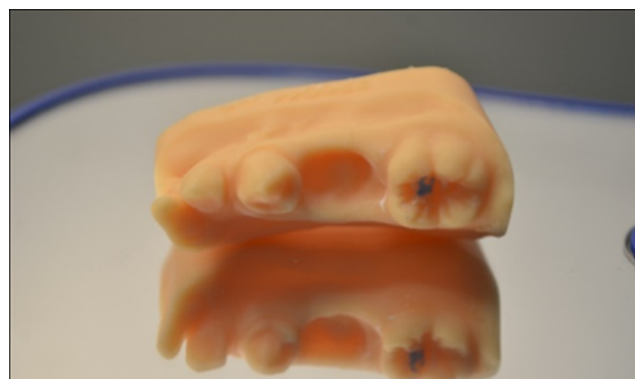

Figure 3: 3D printed model of the desired side

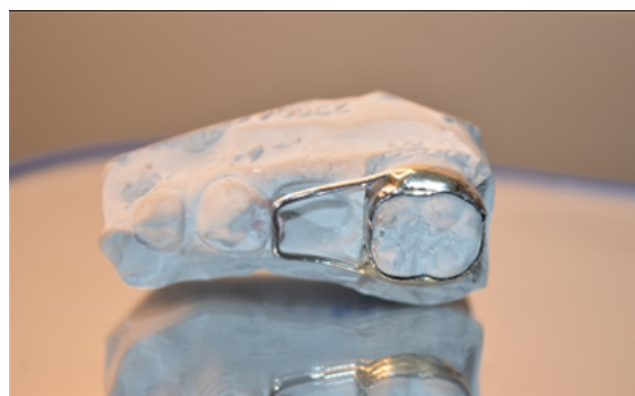

Figure 4: Band and loop space maintainer on cast.

cement (GIC) was done. (Figure 5)

3. Case Report-2

This case presents the use of digital intraoral scanner in fabrication of distal shoe SM in upper arch. A 4.5-year-old child reported to the clinic with a chief complaint of pain in the right upper back tooth region since few days. Clinical examination revealed grossly carious primary maxillary 2nd molar of right side. An OPG was taken which revealed radiolucency i.r.t primary maxillary 2nd molar. (Figure 6)

Looking at the poor prognosis, extraction was planned with placement of willet's appliance or distal shoe SM so as to preserve arch length and maintain space for eruption of permanent successor tooth. Distal shoe SM helps in preventing mesial migration of erupting first molar successor tooth; that is the main role of distal extension in appliance, otherwise erupting first molar will occupy the space. Treatment was explained to the parents and scanning was done before extraction on first appointment by using digital scan. (Figure 7)

Recalled the patient after 5 days, where we already received the SM from lab. After extraction, immediately distal shoe SM was tried in and cemented using GIC. The intra-alveolar projection of the appliance was placed into the

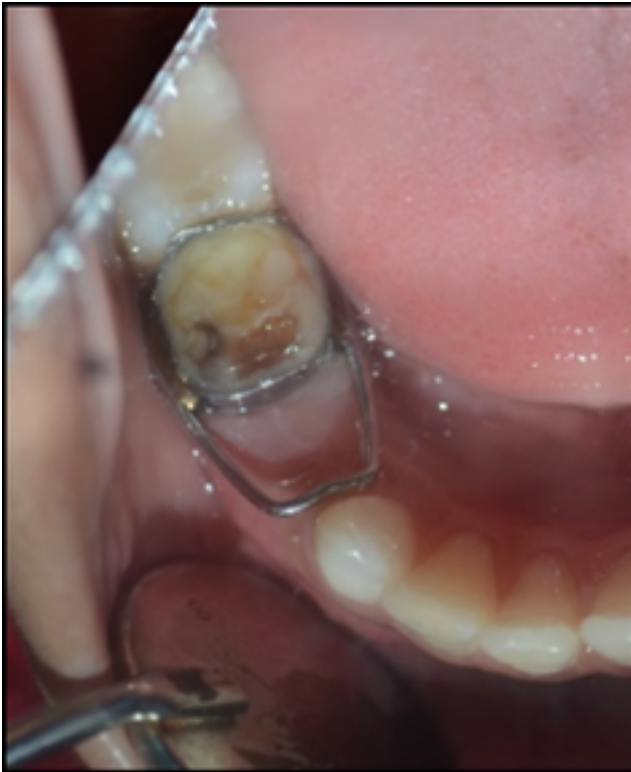

Figure 5: Intraoral placement of appliance.

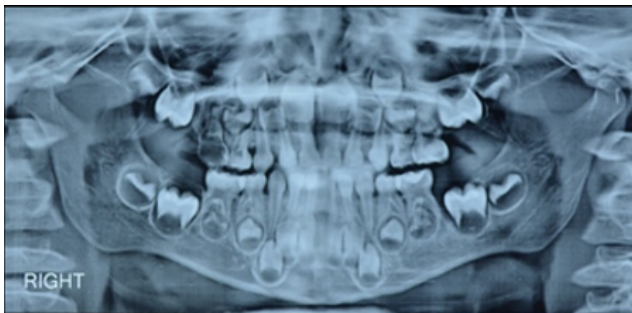


Figure 6: Pre-operative OPG

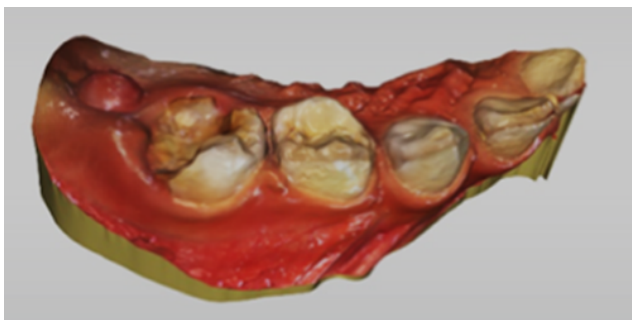


Figure 7: Digital scan using the CEREC Omnicam scanner

socket to touch and guide the vertical eruption guide path for the unerupted permanent 2nd molar. (Figure 8)

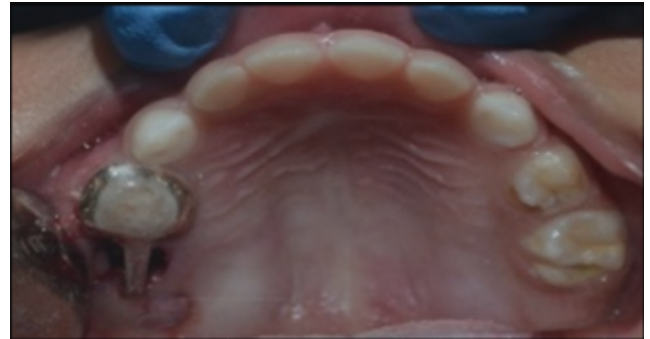

Figure 8: Placement of distal shoe appliance

Intra oral periapical radiograph was taken to check for the passive contact between the mesial end of the permanent 2nd molar and the appliance before cementation. (Figure 9)

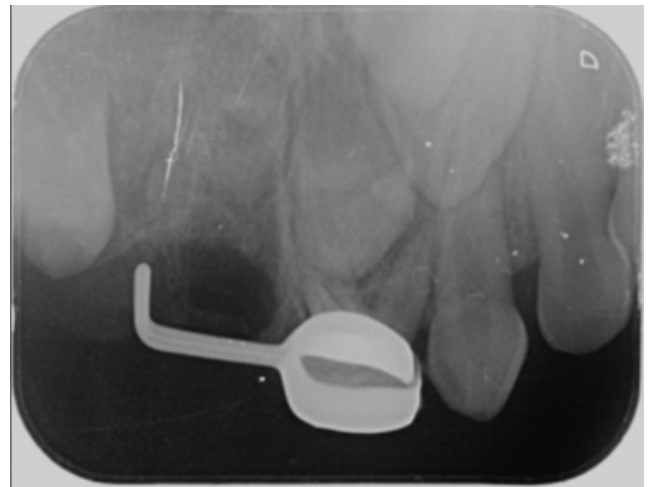


Figure 9: IOPA depicting position of distal shoe

Patient was given instructions and was recalled every 2 months to check for the condition of the appliance.

4. Discussion

Digital impressions improve patient experience and compliance. Digital method reduces chair side time and is helpful in treating non-cooperative patients. SM fabrication remains a routine procedure for clinicians. SM is recommended as an interceptive treatment to reduce complex orthodontic treatment at later ages.² The most common method of making impressions for SM is alginate impression which has disadvantages like transportation difficulties, distortion due to syneresis and imbibition and time consumption.

Conventional SM presents with limitations such as:

- Require minimum two appointments

- Difficult for uncooperative and gag reflex patients
- Technique-sensitive processing stages such as band displacement during cast pouring.⁷

SM is now being fabricated using the digital workflow instead of the traditional analogue workflow to overcome the aforementioned disadvantages.

The use of CAD/CAM technology in pediatric dentistry has shown tremendous success in recent time due to improved patient compliance and acceptance of treatment. The digital technology to take impressions is found to be more convenient and preferred by youngsters than the conventional impression method.⁸ Thus, using modern metal-free ceramic constructs to restore dentition in pediatric patients resulting in stronger, attractive and effective restorations.⁹

In long run CAD/CAM is quick and precise; it may be one of the best options in case of pediatric patients as it will not cause gag reflex and also much easier for uncooperative patients. Another benefit is that the digital impression scan can also be obtained in segments which can be useful in managing non-compliant patients. Digital impression files can be quickly transferred to far-situated laboratories which reduces costs, limits the damage to impressions and models due to shipping and handling. The CEREC system allows dentists to design and fabricate restorations right in the dental clinic.¹⁰

By using this technology, dental restorations and fabrication are made in a single session. Patient can participate in restoration designing procedure suitable for treating children. Despite all the above benefits of digital impression, acquiring the equipment can be expensive and also require fabrication expertise with laboratory assistance.

5. Conclusion

Convention SM like band and loop have disadvantages like increased lab time. The present digital workflow in pediatric dentistry for fabrication of SM is been a swift approach which is easy, precise, and acceptable due to elimination of fabrication stages. Since digital era has arrived offering various advantages so dentists should upgrade its use. Though additional clinical comparative studies are needed, future research should focus on low cost materials.

6. Source of Funding

None.

7. Conflict of Interest

None.

References

1. Barberia E, Lucavechi T. Free end space maintainers: design utilisation and advantages. *J Clin Pediatr Dent.* 2006;31(1):5–8.
2. Brothwell DJ. Guidelines on the use of space maintainers following premature loss of primary teeth. *J Can Dent Assoc.* 1997;63(10):753–66.
3. American Academy of Pediatric Dentistry. In: and others, editor. Management of the developing dentition and occlusion in pediatric dentistry. The reference manual of pediatric dentistry. Chicago, Ill: American Academy of Pediatric Dentistry;; 2020. p. 393–409.
4. Nicholls JJ. The measurement of distortion: theoretical considerations. *J Prosthet Dent.* 1977;37(5):578–86.
5. Powers JM, Wataha JC. Dental Materials: Properties and Manipulation. 10th ed. St. Louis, MO: Elsevier; 2013. p. 248.
6. Halal R, Nohra J, Akel H. Conservative anterior treatment with CAD-CAM technology and polymer-infiltrated ceramic for a child with amelogenesis imperfecta: a 2-year follow up. *J Prosthet Dent.* 2018;119(5):710–12.
7. Tahririan D, Safaripour M, Eshghi A. Comparison of the longevity of prefabricated and conventional band and loops in children's primary teeth. *Dent Res J (Isfahan).* 2019;16(6):428–34.
8. Yilmaz H, Aydin MN. Digital versus conventional impression method in children: Comfort, preference and time. *Int J Paediatr Dent.* 2019;29(6):728–35.
9. Georgieva M, Dimitrov E, Andreeva R. Use of CAD/CAM technologies in pediatric dentistry. *Scripta Scient Med Dent.* 2017;3(2):23. doi:10.14748/ssmd.v3i2.4306.
10. Fasbinder DJ. The CEREC system: 25 years of chairside CAD/CAM dentistry. *J Am Dent Assoc.* 2010;141(2):3–4.

Author biography

Gaurav Gupta, Professor  <https://orcid.org/0000-0003-3895-059X>

D.K Gupta, Senior Consultant

Priyanka Gupta, Senior Demonstrator

Abhishek Khairwa, Professor

Parth Shah, Senior Consultant

Neeraj Chandra, Senior Lecturer

Cite this article: Gupta G, Gupta DK, Gupta P, Khairwa A, Shah P, Chandra N. Transforming pediatric dentistry with digital technology - the way ahead – A case series. *Arch Dent Res* 2023;13(1):53-56.