



Case Report

Central odontogenic fibroma: A case report

Nivedhitha Maraimalai¹*, Manisha Ahire Sardar¹, Shubhangi M Patil¹,
Yogita Adhane¹, Priyanka Pachpande¹, Tabita Joy Chettiankandy¹

¹Dept. of Oral Pathology and Microbiology, Government Dental College and Hospital, Mumbai, Maharashtra, India



ARTICLE INFO

Article history:

Received 15-06-2023

Accepted 18-07-2023

Available online 31-07-2023

Keywords:

Odontogenic tumors

Central odontogenic fibroma

Oral tumours

ABSTRACT

The central odontogenic fibroma (COF) is a rare benign odontogenic mesenchymal tumour of jaw bone derived from the odontogenic ectomesenchyme. It is characterized by a fibrous mature stroma with variable number of strands or islands of inactive-looking odontogenic epithelium. The presented case is a 46 years old male complaining of asymptomatic mandibular bony swelling. Radiographically, the lesion is unilocular radiolucent, with root resorption and displacement of teeth. Histopathology showed dense fibrous connective tissue stroma, loosely arranged with spindle and stellate-shaped mesenchymal cells, inactive odontogenic epithelium island and osteoid tissue. In this case report, we also discuss about the types, pathogenesis, and recent concepts regarding COF.

This is an Open Access (OA) journal, and articles are distributed under the terms of the [Creative Commons Attribution-NonCommercial 4.0 International](https://creativecommons.org/licenses/by-nc/4.0/), which allows others to remix, and build upon the work non-commercially, as long as appropriate credit is given and the new creations are licensed under the identical terms.

For reprints contact: reprint@ipinnovative.com

1. Introduction

World Health Organization (WHO) states Central Odontogenic Fibroma (COF) is a rare benign odontogenic tumour of mesenchymal origin. The odontogenic fibroma (OF) is an elusive and controversial tumour, owing to its rarity and uncertainty due to the number of distinct types that exist.¹ COF is relatively common in females with site predilection in the maxillary anterior region followed by mandibular posterior region.² Radiographic findings are inconclusive as it may range from well-defined radiolucency to mixed radiolucent radio-opaque appearance due to calcifications that overlaps with the features of other odontogenic tumours, thus, emphasizing the necessity for histopathological examination for definitive diagnosis. Here we present a case of central odontogenic fibroma of the mandible with extensive involvement.

2. Case Report

A 46-year-old male patient reported to our institute with the chief complaint of swelling over lower jaw region for 5 months. The swelling gradually progressed to current size. Patient stated history of extraction in mandibular left region (WRT 34,35) 7 years back due to mobility. Extraoral findings were not contributory.

On intraoral examination, diffuse swelling extending from mesial of left mandibular second molar to right mandibular canine crossing the midline and extends lingually over the edentulous area. (WRT 34,35). (Figure 1).

OPG showed well defined unilocular radiolucency along the body of mandible crossing midline, mediolaterally extending from apices of mandibular right second premolar to mesial margin of mandibular left second molar and superoinferiorly from alveolar crest to till inferior border of mandible. Displacement of roots of lower anterior teeth and resorption of mesial and distal roots of left mandibular first molar was evident. Tooth like radio-opacity along inferior border was suggestive of horizontally impacted

* Corresponding author.

E-mail address: nivedhitha19091996@gmail.com (N. Maraimalai).

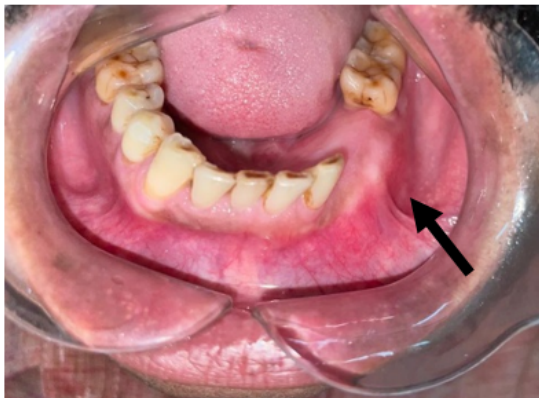


Figure 1: Diffuse swelling extending from mesial of left mandibular second molar to right mandibular canine crossing the midline and extends lingually over the edentulous area

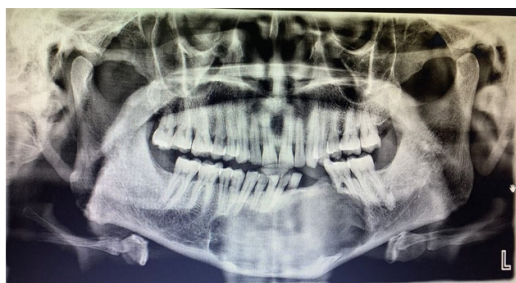

Figure 2: OPG showing well defined unilocular radiolucency extending from apices of mandibular right second premolar to mesial margin of mandibular left second molar and superoinferiorly from alveolar crest to till inferior border of mandible. Tooth like radioopacity along inferior border suggestive of horizontally impacted left mandibular canine. Displacement of roots of lower anterior teeth and resorption of mesial and distal roots of left mandibular first molar noted.

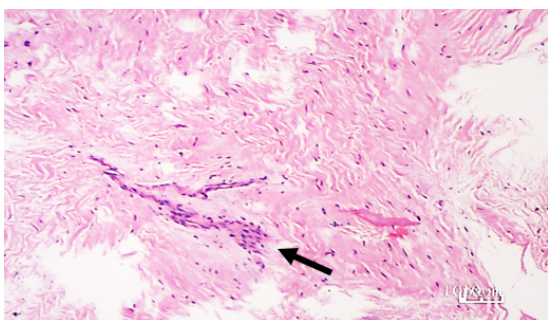


Figure 3: H & E stained section under low power (10x) shows fibrous connective tissue stroma with loosely arranged with spindle and stellate shaped mesenchymal cells. Inactive odontogenic epithelium island (black arrow) is noted.

Table 1: Differences between simple (Non WHO type) and central Odontogenic fibroma (WHO type)^{1,3,4}

Simple central odontogenic fibroma/Non-WHO type/Epithelium poor variant	Central odontogenic fibroma /WHO type/Epithelium rich variant
Derived from dental follicle.	Derived from periodontal ligament.
May exhibit nests of odontogenic epithelium	Odontogenic epithelium is an integral part it may be sparse or conspicuous
Simple type is characterized by a tumor mass made up of mature collagen fibers interspersed usually by many plump fibroblasts that are very uniform in their placement and tend to be equidistant from each other	The WHO type also consists of relatively mature but quite cellular fibrous connective tissue with few to many islands of odontogenic epithelium
Occasionally exhibits calcified material.	Foci of calcifications of the collagenous materials like cementoid, osteoid, and dysplastic dentin noted

left mandibular canine. (Figure 2) Based on clinical and radiographic findings, provisional diagnosis of benign odontogenic tumour was given. Differential diagnosis of Central Giant cell granuloma was considered owing to the extensive extent crossing the midline. Incisional biopsy was done and sent for histopathological examination.

On microscopic examination, dense fibrous connective tissue stroma, loosely arranged with spindle and stellate shaped mesenchymal cells was noted. Few areas showed presence of myxomatous change in the connective tissue stroma. Deeper section showed presence of inactive odontogenic epithelium. Few endothelial lined blood vessels of varying thickness were noted. (Figure 3)

Based on the histopathological findings, final diagnosis of central odontogenic fibroma was given. The lesion was enucleated at a private dental clinic one month ago. The patient is currently under follow up.

3. Discussion

According to the World Health Organization (WHO), Central Odontogenic Fibroma (COF) is a rare benign odontogenic tumour of mesenchymal origin. This tumour consists of mature connective tissue in which islands or strands of inactive-looking odontogenic epithelium can be found with or without evidence of calcification. It was described for the first time by the WHO in 1971. In 1980 Gardner recognized two types of lesion: a simple central odontogenic fibroma and a central odontogenic fibroma (WHO type) which was revised in 2005 by and classified as (1) The WHO variant (containing odontogenic epithelium) (2) The non-WHO variant (without odontogenic epithelium).⁵ The difference between 2 variants are

summarised in Table 1.

Our case was showing features of WHO type variant of central odontogenic fibroma.

Odontogenic fibromas are rare odontogenic tumours with an incidence rate of 0.1%–1.5% of all odontogenic tumours.⁶

As the connective tissue and the epithelial component resemble the periodontal ligament and because of its location, odontogenic fibroma is considered as tumour of periodontal origin. The formation of cementum or bone may indicate differentiation towards the attachment of ligament collagen to cementum and alveolar bone.³

Histomorphology of this tumour generated most confusion. Currently basic concepts have existed concerning this tumour are as follows,

1. Hyperplastic dental follicle- Lesion occasionally associated with impacted tooth resembling dentigerous cyst, few authors regard that as simply a hyperplastic dental follicle and not an odontogenic tumour.
2. Neoplasm- Its histology resemblance to the dental follicle but because of the size which it may attain appearing to constitute a neoplasm.
3. It is a lesion which has been described by WHO as a fibroblastic neoplasm as except for the location its histological features are identical to the peripheral odontogenic fibroma, as described by the WHO.⁷
4. Thoma and Goldman postulated that myxoma resulted from myxomatous degeneration of fibroma. However, according to some authors, in odontogenic fibroma maturation of connective tissue occurs with age, thus can be terminal stage of myxoma
5. But Regezi et al. concluded that histological findings are not age related.⁸

Central odontogenic fibroma reported in wide age groups and frequently diagnosed in patients between the 2nd and 4th decades of life on contrary to the present case it occurred in the 5th decade. Female predilection has been reported predominantly however, few authors claim equal distribution of cases between both the genders.⁹ Maxillary anteriors followed by mandibular posteriors were the most commonly affected sites. However, the current case had an extensive involvement crossing the midline involving both the quadrants of the mandible. Radiographically, the lesions are associated with an unerupted tooth, similar to the current case.⁹

Histological differential diagnosis of COF include desmoplastic ameloblastoma, desmoplastic fibroma, ameloblastic fibroma and odontogenic myxoma due to the presence of strands of odontogenic epithelial islands in connective tissue stroma. Hence, these lesions can be differentiated on the following basis.

1. Desmoplastic ameloblastoma and desmoplastic fibroma-shows excessive desmoplasia in connective tissue.

2. Ameloblastic fibroma-No hard tissue formation.

3. Odontogenic myxoma-Abundant myxoid stroma and no cemental like calcifications.^{1,6}

Subtypes of odontogenic fibroma includes amyloid subtype, granular subtype, ossifying subtype, hybrid odontogenic fibroma with central giant cell granuloma type.^{2,9}

The treatment of this neoplasm is surgical enucleation and curettage with extraction of involved teeth. The lesion shows minimal tendency to recur and has good prognosis.⁶

4. Conclusion

Due to its rarity and overlapping clinical and radiological features, COF may be misdiagnosed as certain aggressive lesion. Thus, histological diagnosis becomes important. It becomes important to differentiate it from other lesions like odontogenic myxoma, desmoplastic ameloblastoma as these tumours requires aggressive treatment as compared to odontogenic fibroma. This case report elucidates the importance of the histologic diagnosis of any neoplasm apart from their routine clinical and radiographic diagnosis.

5. Source of Funding

None.


6. Conflict of Interest


None.


References

1. Philipsen HP, Reichart PA, Sciubba JJ, Van Der Wall I. World Health Organization Classification of Tumours. Pathology and Genetics of Head and Neck Tumours. Barnes L, Eveson JW, Reichart P, Sidransky D, editors. Lyon, France: IARC Press; 2005. p. 317.
2. Tekkesin MS, Wright JM. The World Health Organization Classification of Odontogenic Lesions: A Summary of the Changes of the 2022 (5th) Edition. *Turk Patoloji Derg.* 2022;38(2):168–84.
3. Gardner DG. Central odontogenic fibroma current concepts. *J Oral Pathol Med.* 1996;25(10):556–61.
4. Rajendran R. Shafer's textbook of oral pathology. 6th ed. and others, editor. Elsevier India; 2009. p. 540.
5. Bennabi S, Lesclous P, Cloitre A. Central odontogenic fibroma: characteristics and management. *J Oral Med Oral Surg.* 2021;27(2):1–9.
6. Singh J, Singh S, Chandra S. Central odontogenic fibroma: A case report with histopathological differential diagnosis. *Int J Oral Health Sci.* 2021;10(4):e2556. doi:10.7759/cureus.2556.
7. Neville BW, Damm DD, Allen CM, Chi AC. Oral and Maxillofacial Pathology. 4th ed. and others, editor. Elsevier Health Sciences; 2015. p. 928.
8. El-Labban NG, Kw L, Kramer I.R.H. The duality of the cell population in a calcifying epithelial odontogenic tumour (CEOT). *Histopathology.* 1984;8(4):679–91.
9. Veravarmal V, Madhavan RN, Nassar MM, Amsaveni R. Central odontogenic fibroma of the maxilla. *J Oral Maxillofac Pathol.* 2013;17(2):319.


Author biography


Nivedhitha Maraimalai, Post Graduate Student  <https://orcid.org/0000-0003-1208-3088>

Manisha Ahire Sardar, Associate Professor (Academic)  <https://orcid.org/0000-0003-2003-1544>

Shubhangi M Patil, Post graduate Student  <https://orcid.org/0009-0002-1270-0189>

Yogita Adhane, Assistant Professor

Priyanka Pachpande, Assistant Professor  <https://orcid.org/0000-0003-0382-0779>

Tabita Joy Chettiankandy, Professor and Head  <https://orcid.org/0000-0002-6839-6959>

Cite this article: Maraimalai N, Sardar MA, Patil SM, Adhane Y, Pachpande P, Chettiankandy TJ. Central odontogenic fibroma: A case report. *Arch Dent Res* 2023;13(1):45-48.