



Case Report

Management of dilacerated root canals — A challenge to endodontist

Kalyani G Umale^{1*}, Vandana J Gade¹

¹Dept. of Conservative Dentistry and Endodontics, Swargiya Dadasaheb Kalmegh Smruti Dental College and Hospital, Nagpur, Maharashtra, India



ARTICLE INFO

Article history:

Received 12-11-2022

Accepted 05-01-2023

Available online 20-02-2023

Keywords:

Dilacerated canals

CBCT

Curved canals

ABSTRACT

The unique morphology of dilacerated and S-shaped root canals often poses utmost challenges in their endodontic management. Dilaceration is defined as developmental anomaly in which there has been an abrupt change in the axial inclination between the crown and the root of a tooth. Periapical radiographs and CBCT are the most appropriate way to diagnose the presence of root dilacerations. Also, clinician is required to have an insight of the morphology of tooth related to its shape, form and structure before commencing treatment. This article is an attempt to review root dilaceration as well as two interesting case reports of root dilacerations.

This is an Open Access (OA) journal, and articles are distributed under the terms of the [Creative Commons Attribution-NonCommercial 4.0 International](https://creativecommons.org/licenses/by-nc/4.0/), which allows others to remix, and build upon the work non-commercially, as long as appropriate credit is given and the new creations are licensed under the identical terms.

For reprints contact: reprint@ipinnovative.com

1. Introduction

Success of endodontic treatment depend upon thorough shaping and cleaning of the root canal system. One of the most important stages in endodontic treatment is the biomechanical preparation of the root canal system.¹ In deal root canal preparation, one should maintain the original canal morphology during the biomechanical preparation, along with the development of flaring from coronal to the apical portion and preserving the apical foramen. However, due to the complexity of the root canal anatomy the ideal root canal preparation may not be always possible.^{2,3}

It is difficult to find a tooth with a straight root and a straight root canal Multiple curvatures of root canal poses difficulty in canal instrumentation.⁴ Various root canal curvatures create a challenge in biomechanical preparation during endodontic treatment. These curved root canal leads to limitation of the ideal mechanical preparation of the root canals and in turn may lead to the development of some procedural errors.⁵

In 1848, Tomes, coined the term “dilacerations”. It is an angulation or a sharp bend or a curve in the root or crown of formed tooth or a deviation or bend in the linear relationship of a crown of a tooth to its root.⁶ This condition occurs due to trauma during the period in which tooth is forming. The result is that the position of the calcified portion of the tooth is changed and the remainder of the tooth is formed at an angle.⁴ Undesirable accidents such as ledge formation, blockages, perforations and apical transportation have been observed to occur after preparation of curved canals. Management of such curved canals is an endodontic challenge; so, for a successful therapy, a thorough knowledge of root and root canal morphology is required.⁷ The current case series presents two cases with curved root canals treated successfully.

2. Case Report 1

A 45-year-old male reported to the Department of Conservative Dentistry and Endodontics, with pain in relation to upper left posterior teeth. Clinical examination revealed maxillary left first and second premolars having

* Corresponding author.

E-mail address: kalyaniumale@gmail.com (K. G. Umale).

caries. First premolar was tender on percussion. Medical history was non-contributory. Radiographic examination revealed that the caries was extending into the pulp chamber of first premolar. The roots of 24 showed a sharp curvature at middle third (Figure 1). From the clinical and radiographic findings, a diagnosis of symptomatic apical periodontitis was made in relation to 24 and the root canal treatment was advised. Prior to the formulation of endodontic therapy, the degree of curvature was determined by using Schneider method and it showed severely curved canals in relation to 24.

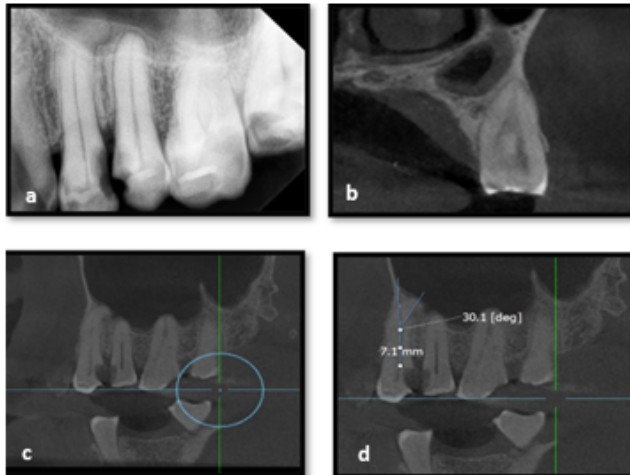


Figure 1: a:) Preoperative radiograph showing dilacerated root canal in relation to 24. CBCT image showing b:) Cross sectional view c:) sagittal view d:) measurement of root curvature (Schneider's method) of 24.

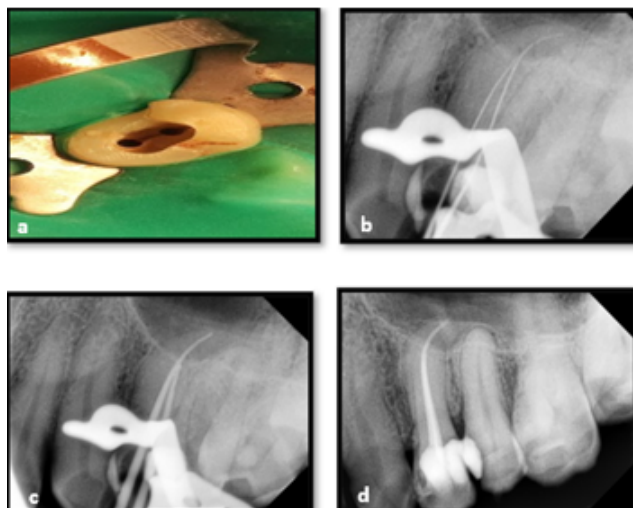


Figure 2: a:) Intraoral photograph of access opening, b:) Working length radiograph, c:) Master cone radiograph, d:) Post obturation radiograph.

Local anesthesia was given using 2% lignocaine and 1:100000 Adrenaline and Endodontic therapy was initiated under rubber dam isolation. After gaining an adequate access (Figure 2 a), 8 & 10 no. K-files were used for initial inspection of the root canal, and the patency of root canal was established. The working length was estimated using an electronic apex locator and confirmed with radiograph (Figure 2 b). The initially 10 and 15 K files (Mani, Inc, Japan) were used and filing sequence was done with 17% EDTA followed by irrigation with saline and 3% sodium hypochlorite (NaOCl). The canals were further enlarged with 17(V04), 20(V06) and 25 (V06) V Taper files (SS White® V-Taper™ 2 H NiTi Rotary Endodontic File System). Final preparation was carried out using Cricendo files (Cricidental, India) up to 4% taper 25 size of the instrument. EndoActivator was used for irrigation activation. Calcium hydroxide was used as an intracanal medicament and closed dressing was given for seven days. In the next visit, the canals were cleaned with saline and dried with paper points. Single cone obturation was done with 25 size 4% taper gutta-percha (Figure 2 c) along with zinc oxide eugenol sealer. The post obturation restoration was done using Composite (Figure 2 d).

3. Case Report 2

A 32-year-old female reported to the Department of Conservative Dentistry and Endodontics, with pain in relation to upper left posterior teeth. Clinical examination revealed maxillary left second premolars having caries. Tooth was tender on percussion. Medical history was non-contributory. Radiographic and CBCT examination revealed that the caries was extending into the pulp chamber of second premolar. The roots of 25 were doubly curved (Bayonet or 'S' shaped) (Figure 3 a, b). From the clinical and radiographic findings, a diagnosis of symptomatic apical periodontitis was made in relation to 25 and the root canal treatment was advised.

Local anesthesia was given using 2% lignocaine and 1:100000 Adrenaline and Endodontic therapy was initiated under rubber dam isolation. After gaining an adequate access (Figure 3 c), 8 & 10 no. K-file were used for initial inspection of the root canal and the patency of root canal was established. The working length was estimated using an electronic apex locator and confirmed with radiograph (Figure 3 d). The initially 10 and 15 K files (Mani, Inc, Japan) were used and filing sequence was done with 17% EDTA followed by irrigation with saline and 3% sodium hypochlorite (NaOCl). Final preparation was carried out using Cricendo files (Cricidental, India) up to 4% taper 25 size of the instrument. EndoActivator was used for irrigation activation. Calcium hydroxide was used as an intracanal medicament and closed dressing was given for seven days. In the next visit, the canals were cleaned with saline and dried with paper points. Single cone obturation was done

with 25 size 4% taper gutta-percha (Figure 4 a) along with zinc oxide eugenol sealer. The post obturation restoration was done using Composite (Figure 4 b).

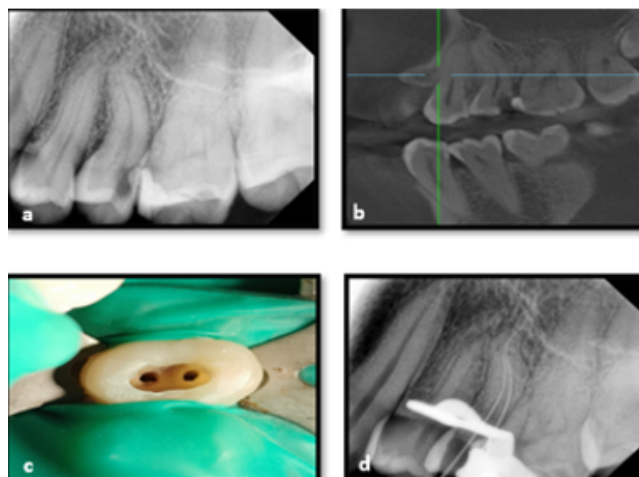


Figure 3: a:) Preoperative radiograph showing doubly curved (Bayonet or 'S' shaped) root canal in relation to 25, b:) CBCT image showing curved canals of 25, c:) Intraoral photograph of access opening, d:) Working length radiograph.

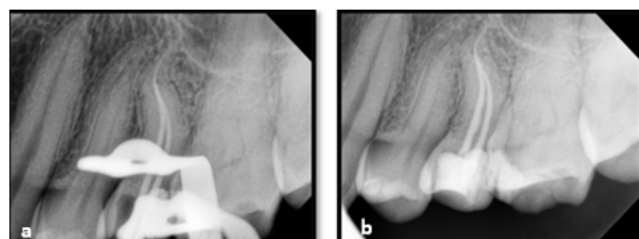


Figure 4: a:) Master cone radiograph, b:) Post obturation radiograph of 25.

4. Discussion

Thorough cleaning and disinfection of the entire root canals system is important for success of any endodontic procedure. Most of the teeth tend to exhibit some sort of curvature and multiple planes of deviations along the course of the root canal length.¹ However, the root canal curvature leads to difficulty in root canal instrumentation and in turn compromises the successful endodontic treatment.⁷

Tomes specified the broad term of root canal curvatures as dilaceration. It is defined as any kind of angulation or any sharp bend or any curve in the root or crown of the formed tooth. The tooth is considered to be dilacerated if the direction of the curved root is 90° or more to the long axis of the tooth and if the apical portion of the root is curved about 20° or more to the long axis of the tooth. The traumatic injuries during the tooth development are the main etiologic factor for the dilacerated roots.⁸

The root canal curvatures vary depending on the location or severity, the curvatures may be apical or gradual or S shaped.⁹ The endodontic complications are usually observed with the improper handling of the instruments or improper techniques of instrumentations such as the ledge formations, canal blockages, root canals perforations, and apical transportations. Thus, evaluation of degree of root canals curvatures in the diagnostic radiograph or in the CBCT prior to initiation of root canal procedure aids in the successful treatment.¹⁰

In 1971, Schneider has proposed a method of determination of root canal curvatures based on the preoperative radiographs. According to Schneider's method, first a line parallel to the long axis of canal in the coronal third of root canal is drawn, a second line is drawn from the apical foramina to intersect the first line. Then, Schneider's angle was determined at the intersection of these lines on a hard copy of the diagnostic radiograph.¹¹ Accordingly, based on the angle of the curvatures the root canal curvatures are classified as straight (5° or less), moderate (10°–20°), and severe (25°–70°).¹²

The degree of curvatures were determined for all the cases presented in the current case series. It was found that they fall under the severe type of canal curvatures. The severe curvatures presented in the above cases warrant a careful biomechanical preparation to prevent the endodontic complications. Progressive taper is the most desirable shape of the prepared root canal with largest diameter is at the coronal end and narrowest at the apical constriction. A progressive tapering of root canal allows a greater degree of instrument and irrigant contact with the surfaces of the canal walls, thereby enhancing the effectiveness of cleaning.¹³ According to Gutmann coronal pre-flaring helps in easy negotiation of the entire curved canal.⁷ The cases presented above were treated with hand instrumentation with K files and NiTi rotary instruments. It is important to note that a tooth with complex root canal morphology should be treated properly in the very first time, since endodontic treatment in such teeth is likely to fail if not treated carefully.

5. Conclusion

Severe root curvature may lead to difficulty in cleaning and shaping as well as obturation of the root canal. A thorough knowledge about internal anatomy of the tooth, appropriate instrumentation techniques and customized treatment planning depending upon the degree of curvature will help manage curved canals, prevent complications and enhance the quality of the treatment.

6. Source of Funding

None.

7. Conflict of Interest

None.

References

1. Ruddle C. Cleaning and shaping the root canal system. In: Cohen S, Burns R, editors. *Pathways of the Pulp*. St. Louis, MO: Mosby; 2002. p. 231–92.
2. Peters OA. Current challenges and concepts in the preparation of root canal systems: A review. *J Endod*. 2004;30(8):559–67.
3. Estrela C, Bueno MR, Sousa-Neto MD, Pécora JD. Method for determination of root curvature radius using cone-beam computed tomography images. *Braz Dent J*. 2008;19(2):114–8.
4. Jafarzadeh H, Abbott PV. Dilaceration: review of an endodontic challenge. *J Endod*. 2007;33(9):1025–55.
5. Mounce R. Negotiating challenging mid root curvatures: Rounding the bend. *Dent Today*. 2007;26(2):108–10.
6. Hamasha AA, Al-Khateeb T, Darwazeh A. Prevalence of dilaceration in Jordanian adults. *Int Endod J*. 2002;35(11):910–2.
7. Jain N, Tushar S. Curved canals: ancestral files revisited. *Indian J Dent Res*. 2008;19(3):267–71.
8. Walia PS, Rohilla AK, Choudhary S, Kaur R. Review of dilaceration of maxillary central incisor: A multidisciplinary challenge. *Int J Clin Pediatr Dent*. 2016;9(1):90–8.
9. Ruddle CJ. The ProTaper endodontic system: Geometries, features, and guidelines for use. *Dent Today*. 2001;20(10):60–7.
10. Ye J, Gao Y. Metallurgical characterization of M-wire nickel-titanium shape memory alloy used for endodontic rotary instruments during low-cycle fatigue. *J Endod*. 2012;38(1):105–12.
11. Johnson E, Lloyd A, Kuttler S, Namerow K. Comparison between a novel nickel-titanium alloy and 508 nitinol on the cyclic fatigue life of ProFile 25/.04 rotary instruments. *J Endod*. 2008;34(11):1406–15.
12. Peters OA. Current challenges and concepts in the preparation of root canal systems: A review. *J Endod*. 2004;30(8):559–67.
13. Schilder H. Cleaning and Shaping of the root canals. *Dent Clin N Amer*. 1974;18(2):269–96.

Author biography

Kalyani G Umale, Post Graduate Student

Vandana J Gade, Professor

Cite this article: Umale KG, Gade VJ. Management of dilacerated root canals — A challenge to endodontist. *Arch Dent Res* 2022;12(2):115-118.