



## Case Report

# Sialadenitis associated with Sialolith- A Case Report

**Mrunali Jambhulkar<sup>1,\*</sup>, Devendra Palve<sup>1</sup>, Deepali Mohite<sup>1</sup>, Snehal Udapure<sup>1</sup>,  
Vinanti Bodele<sup>1</sup>, Vaishnavi Borkar<sup>1</sup>**

<sup>1</sup>Dept. of Oral Pathology and Microbiology, Swargiya Dadasaheb Kalmegh Smruti Dental College & Hospital, Nagpur, Maharashtra, India



### ARTICLE INFO

#### Article history:

Received 20-08-2021

Accepted 10-09-2021

Available online 31-12-2021

#### Keywords:

Sialolithiasis

Histopathological

Sialolith

### ABSTRACT

Sialadenitis is the inflammation of the major salivary glands. It is an insidious inflammatory disease of the major salivary glands which may lead to the development of fibrous masses. The most frequent cause of sialadenitis is the presence of a salivary duct calculi, the sialolith. Sialolithiasis is the presence of stones in the salivary gland. It presents with pain and tenderness in the affected area. A 56-year old male patient had reported in the department with pain and swelling in the right lower back region of the jaw since 7 days. On clinical, radiographic and histopathological examination, a case of sialolith was reported in the right submandibular gland along with sialadenitis.

This is an Open Access (OA) journal, and articles are distributed under the terms of the [Creative Commons Attribution-NonCommercial-ShareAlike 4.0 License](https://creativecommons.org/licenses/by-nc-sa/4.0/), which allows others to remix, tweak, and build upon the work non-commercially, as long as appropriate credit is given and the new creations are licensed under the identical terms.

For reprints contact: [reprint@ipinnovative.com](mailto:reprint@ipinnovative.com)

## 1. Introduction

Inflammation of the salivary gland is a usual presentation. Most of the conditions of the salivary glands involve predominantly the parotid gland followed by the submandibular and sublingual gland. Inflammation of the salivary glands is termed Sialadenitis. It is an insidious inflammatory disease of the major salivary glands characterized by intermittent swelling of the glands. The most common etiology is thought to be of viral infection including Coxsackie A, ECHO and cytomegalovirus.<sup>1</sup> One of the more common causes of sialadenitis is recent surgery, after which acute parotitis may arise. It may be of acute or chronic onset. Most cases of acute bacterial sialadenitis are due to *Staphylococcus aureus*, other streptococci may also be responsible. Adults and children, both are affected by this condition. Children present it as mumps. In adults, the most frequent cause of chronic sialadenitis is the occurrence

of salivary duct calculi with subsequent pyogenic bacterial infection. They are known as sialolith. These are calcified structures that develop within the salivary ductal system which rise from the

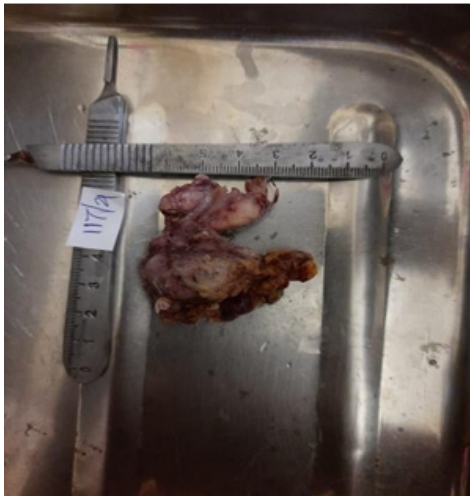deposition of calcium salts around a nidus of debris within the duct lumen in young and middle-aged adults. These most often develop within the ductal system of the submandibular gland due to its long, torturous, upward course. The occlusion of the duct prevents the free flow of saliva, and this stagnation or accumulation of saliva under pressure produces pain and swelling.<sup>2</sup> Radiographically, sialoliths appear as radiopaque masses.

## 2. Case Report

A 56-year old male patient reported in the department with a complaint of pain and swelling in the right lower right back region of the jaw since 15 days. On clinical examination, a diffuse swelling of approximately 25mm\*30 mm in size was noticed in the right submandibular region. The swelling extended from 2 cm below the lower border of the mandible

\* Corresponding author.

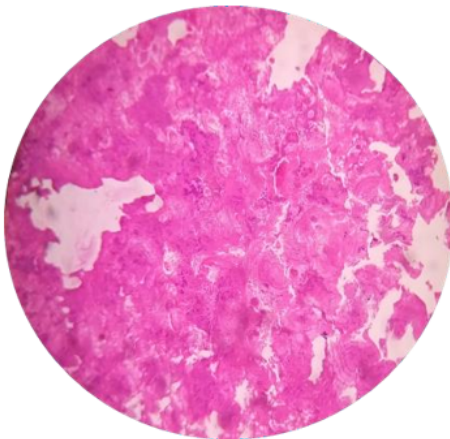
E-mail address: [mrnali.jambhulkar@sdk-dentalcollege.edu.in](mailto:mrnali.jambhulkar@sdk-dentalcollege.edu.in) (M. Jambhulkar).



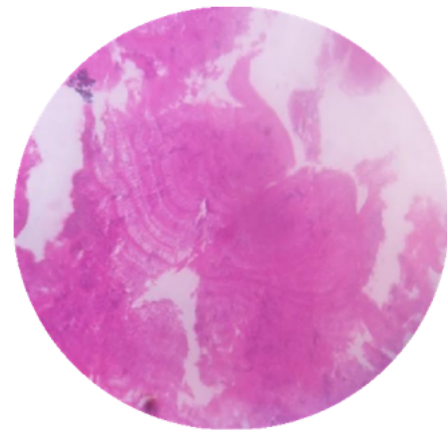
**Fig. 1:** The resected submandibular gland.



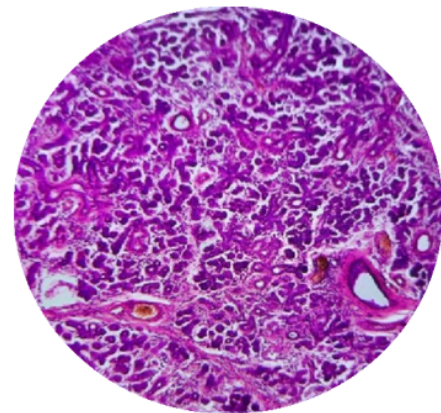
**Fig. 2:** Sialolith of size approximately 5mm\*10mm



**Fig. 3:** Concentric laminations seen around a central nidus (10X view)



**Fig. 4:** Concentric laminations (40 X view)



**Fig. 5:** Periductal inflammation around salivary gland duct (10X view)

to the lower border of the thyroid cartilage. A small swelling was seen in the floor of mouth. The patient also has pain in the right submandibular region before and while eating food. A provisional diagnosis of a sialolith with sialadenitis was made. Radiographic examination revealed a radiopaque mass in the right submandibular region of approximately 5mm\*10 mm in size. Oral antibiotics and analgesics were prescribed for 7 days to reduce the pain. On follow-up after 7 days, the swelling had subsided, resection of the submandibular gland was done (Figure 1). A sialolith was observed in the floor of the mouth. The excised sialolith was then sent for histopathological examination to confirm the diagnosis. A cylindrical shaped sialolith was received for grossing, approximately 5mm\*10 mm in size of a stony hard consistency. (Figure 2). The sialolith was decalcified first in 5% nitric acid and then sectioned followed by staining with haematoxylin and eosin for histopathological examination.

On the H&E stained section, the calcified mass exhibited concentric laminations around a central nidus of amorphous debris (Figures 3 and 4). Periductal inflammation is also

seen (Figure 5). The successive deposition of inorganic and organic material lead to the concentric formation.

### 3. Discussion

The occurrence of a stone (sialolith) in the salivary gland or ducts is known as sialolithiasis. It is a common cause of salivary gland disease with a prevalence rate of approximately 1.2%. Stones occur as a result of calcification of an intraluminal organic nidus such as dried secretion, bacterial colonies, and cellular debris. Stagnation of salivary flow, high alkalinity, and increased calcium content predispose to sialolith formation.<sup>3</sup> Salivary gland calculi are more commonly found in submandibular gland than parotid gland due to factors such as the direction of salivary flow, a tortuous structure of Wharton duct and the high calcium and mucin content of saliva produced in the submandibular gland.<sup>4</sup> The size of salivary gland calculi vary from small particles to large concretment formations. The average size of the salivary calculi lies between 3 mm and 17 mm. They are usually located in the ducts of the gland and the hilus, whereas sialolith in the parenchyma occurs in 9-17% of all cases.<sup>5</sup> It is the most common cause of acute and chronic infection in the major salivary glands. Sequelae of long-standing calculi include sialadenitis, duct dilation, gland atrophy, and potentially profound cystic dilatation. Other causes of infection in salivary glands are a variety of microbial agents including bacteria, mycobacteria, viruses, fungi, parasites, and protozoa.<sup>6</sup>

A prompt management is the key. The primary objective of the treatment of sialolithiasis is the restoration of normal salivary secretion. The treatment options for submandibular sialoliths are intraoral removal of stone, interventional sialendoscopy and resection of the gland. The appropriate treatment method is chosen according to size, location, and number of sialoliths. Newer treatment modalities such as endoscopic intracorporeal shockwave lithotripsy and extracorporeal shockwave lithotripsy have been introduced as alternatives to conventional submandibular gland surgery. Sialendoscopy has been used as both a diagnostic and an interventional modality in salivary sialolithiasis. Small salivary intraductal calculi may be removed and biopsies may be taken using sialendoscopy systems.<sup>4</sup>

In this case, a long standing sialolith lead to sialadenitis. The patient presented with typical signs and symptoms of sialadenitis associated with a sialolith and the radiographic and histopathologic findings also confirmed the same. The affected salivary gland was removed and the sialolith extracted from the floor of the mouth. The antibiotic coverage subsided the swelling and then the gland was excised after obtaining the patient's consent. Post-operative

follow-up is important to ensure stone-free salivary glands and fewer chances of infection and inflammation in the salivary glands due to calculi.

### 4. Conclusion

Association of the presenting signs and symptoms along with the clinical appearance of hard swelling in the submandibular region should be properly managed and assessed. The presence of a salivary gland calculi must be diagnosed beforehand to decrease the risk of a subsequent salivary gland infection like sialadenitis which may further have detrimental effects.

### 5. Source of Funding

None.

### 6. Conflict of Interest

None.

### References

1. Neville B, Damm D, Allen C, Bouquot J. Oral and Maxillofacial Pathology; 2015. p. 393–6.
2. Rajendran R. Shafer's Textbook of Oral Pathology. New Delhi; 2009. p. 345.
3. Chandak R, Degwekar S, Chandak M, Rawlani S. 2012.
4. Arslan S, Vuralkan E, Çobanog A, Ural A. Giant sialolith of submandibular gland: report of a case. *J Surgical Case Rep.* 2015;2015(4):43.
5. Jung JH, Hong SO, Noh K, Lee DW. A large sialolith on the parenchyma of the submandibular gland: A case report. *Experimental and therapeutic medicine.* *Exp Ther Med.* 2014;8(2):525–31. doi:10.3892/etm.2014.1730.
6. Gnepp D. Diagnostic Surgical Pathology of the Head and Neck; 2001. p. 426–53.

### Author biography

**Mrunali Jambhulkar, MDS**

**Devendra Palve, Professor**

**Deepali Mohite, Reader**

**Snehal Udupure, MDS**

**Vinanti Bodele, MDS**

**Vaishnavi Borkar, MDS**

**Cite this article:** Jambhulkar M, Palve D, Mohite D, Udupure S, Bodele V, Borkar V. Sialadenitis associated with Sialolith- A Case Report. *Arch Dent Res* 2021;11(2):130-132.