



Review Article

Revolutionizing periodontal procedures: The potential of piezoelectric devices

Aswathy Jayasree^{1*}, Raseena Beevi¹, Roshni Ramesh¹, Ajith Kumar K C¹,
Shruthi Reghunath¹, Bilha Joy¹, Abdurasheed E M¹

¹Government Dental College, Thiruvananthapuram, Kerala, India



ARTICLE INFO

Article history:

Received 11-04-2024

Accepted 18-06-2024

Available online 05-07-2024

Keywords:

Bone Graft

Curettage

Implant

Microsurgery

Piezosurgery

ABSTRACT

Piezosurgery, a minimally invasive surgical technique introduced two decades ago, has found extensive applications in dentistry. Its primary advantage lies in enhancing patient comfort while safeguarding vital structures. Within Periodontics and implant dentistry, the piezosurgery unit has become indispensable, facilitating procedures ranging from scaling and root planning to complex surgeries like resective osseous surgery, bone harvesting, sinus lifts, ridge splitting, and implant placements. This innovative device holds promise for delivering better and more predictable clinical outcomes in various osseous surgical procedures. This article explores the utilization of piezosurgery in Periodontics and implant dentistry, delving into its mechanism, advantages, and limitations.

This is an Open Access (OA) journal, and articles are distributed under the terms of the [Creative Commons Attribution-NonCommercial 4.0 International](https://creativecommons.org/licenses/by-nc/4.0/), which allows others to remix, and build upon the work non-commercially, as long as appropriate credit is given and the new creations are licensed under the identical terms.

For reprints contact: reprint@ipinnovative.com

1. Introduction

Periodontitis is an inflammatory condition affecting the tissues around the teeth, characterized by alveolar bone resorption. This condition leads to alterations in bone morphology and may result in reverse bony architecture. These alterations significantly impede the removal of causative factors and the restoration of normal bone morphology.

In regions where bone density is diminished, manual tools were employed to delicately remove small portions of bone. Nevertheless, they pose challenges in situations where precise osseous surgery is needed. So, they were mainly used for contouring larger osseous segments. Powered instruments are often used in bone with high density. Osseous surgeries were performed utilizing manual tools and various rotary instruments with diverse burs, necessitating ample external copious irrigation to counteract the production of heat using these instruments.

In osseous surgery, substantial force needs to be applied, which can be problematic with fractured or fragile bones. To tackle these challenges, a cutting-edge surgical technique emerged harnessing ultrasonic microvibration for accurate, tissue-conserving bone cuts, which is known as Piezosurgery. This innovative method involves piezoelectric technology, where a metallic tip vibrates at high frequency to selectively cut bone, preserving nearby soft tissues.

Piezosurgery, a technique pioneered by Professor Vercellotti in the year 1988, presents significant benefits and tackles the limitations of conventional instruments in intraosseous surgery by improving the traditional technique of ultrasound.¹ The fundamental concept of piezoelectricity initially identified by Jacques and Pierre Curie in the late 1800, for bone reduction is based on ultrasonic microvibrations. The phenomenon of specific crystals and ceramics deforming when exposed to an electric current, leading to ultrasonic frequency oscillations, is termed the piezoelectric effect. Ultrasonic vibrations have been used routinely for standard clinical applications in many different fields of surgery in only the last 5- 6 years.

* Corresponding author.

E-mail address: aswathydhanu24@gmail.com (A. Jayasree).

2. History

The term "piezo" finds its origin in the Greek word "piezein," which translates to "to press tight or squeeze." In 1880, Jacques and Pierre Curie pioneered the exploration of piezoelectricity and found that applying pressure on diverse materials like crystals, ceramics, or bone results in the production of electricity. Ultrasound technology was first used by Pohlman in 1950 for the treatment of myalgias and neuropathic pain, and he published the first study. Catuna in 1953 was the first one to apply ultrasound in the field of dentistry for cutting tooth structure.

In 1957, Richman first documented the application of an ultrasonic chisel, without slurry, for bone elimination and root resection during apicoectomies. Following this, three years later, Mazzarow presented evidence of an ultrasonic blade resembling a scalpel capable of directly cutting osseous tissue. Ultrasonic was introduced in the field of Periodontics by Zinner in 1955. Vercellotti in 1997 introduced the ultrasonic device for periradicular osteotomy to extract ankylosed root of a maxillary canine. The first generation Piezosurgery device was developed by Mectron in 2000, and the second and third generation in 2004 and 2009 respectively.

The first study about sinus lift was presented in 2001 and the first implant site preparation using Piezosurgery device was done in 2005. Gabriel Lippmann's discovery in 1881 unveiled the converse piezoelectric effect, which spurred further investigations by numerous scientists. The piezoelectric effect relies on fundamental interactions between electric and mechanical properties, including electric field strength, polarization, tension, and extension within a crystalline structure. This phenomenon asserts that when an alternating electric current flows through a crystal, it induces deformation, resulting in ultrasonic frequency vibrations. These vibrations generated are enhanced and directed towards a vibrating tip. When this tip applies gentle pressure on bone, it induces cavitation phenomena, leading to a cutting effect specifically on the mineralized tissue. In 1953, Catuna spearheaded the advancement of an ultrasonic drill tailored for cavity preparation in human teeth. Additionally, Catuna elucidated the impacts of ultrasound on dental hard tissues. In 1961, McFall et al. assessed healing differences by comparing rotating instruments with oscillating scalpel blades, noting slower healing with the latter but without severe complications.² In 1980, Horton et al. suggested enhanced bone regeneration with the utilization of ultrasonic devices. Later, he evaluated the clinical effectiveness of ultrasonic instrumentation in bone surgery, observing efficient mineralized tissue removal and positive patient acceptance without complications.³

In 1998, Torella highlighted the superior performance of an ultrasonic generator over a magnetostrictive device due to its higher cutting efficiency and reduced bone destruction.⁴ Dr. Thomas Vercellotti in 1999 pioneered

piezoelectric bone surgery in collaboration with Mectron Spa.⁵ By 2002, the device received commercial approval in Germany. Subsequently, in 2003, he identified the optimal frequency approach for orthopedic, neurologic, endodontic, periodontal, and oral and maxillofacial surgery. By 2005, the US Food and Drug Administration broadened the scope of ultrasonics in dentistry to include osseous surgery.

3. Mechanism

The piezoelectric effect is a phenomenon which defines that certain ceramics and crystals when subjected to electric current, undergo deformation that results in the vibrations of ultrasonic frequency. The oscillations are then intensified and transferred to a tip which vibrates when applied to bone with gentle pressure, inducing a mechanical cutting effect described as cavitation that occurs exclusively on mineralized tissue.⁶

The piezosurgery unit boasts approximately thrice the power of a conventional ultrasonic dental unit, which enables it to effectively cut dense cortical bone. These units typically come equipped with holders for the handpiece and irrigation fluids, ensuring efficient and precise operation during surgical procedures. These precise vibrations, combined with power exceeding 5W, facilitate meticulous bone cutting with minimal damage to surrounding tissues. Hand piece tips are activated by a foot switch. The frequency of about 25- 30kHz causes microvibrations of 60 -210 μ m amplitude with power exceeding 5W.

There are several tool tips of varying sizes, shapes and materials which can be controlled with Titanium/ Diamond of varying gradation. The piezosurgery unit offers diverse application modes for different surgical needs. The low mode is tailored for apical root canal treatment; high mode is optimal for clearing and refining bone borders. The boosted mode is for extensive bone reduction like osteoplasty and osteotomies. There should be sufficient irrigation to prevent excessive heating of the bone. Refrigerating the solution to 4°C enhances its cooling capabilities, crucial for maintaining optimal surgical conditions. This cooled solution efficiently removes debris from the cutting area, promoting precise cuts and preserving a blood-free surgical environment. These benefits are facilitated by the cavitation process initiated by the irrigation solution, ensuring effective debris clearance and overall procedural efficiency.

4. Characteristics of Piezosurgery instruments

A Piezosurgery unit consists of mainly four parts, a main body, a foot pedal, a handle, and a range of inserts designed with unique shapes to meet specific surgical needs.

4.1. Main body

The main body includes an electronic display screen, a touchpad interface, a peristaltic pump mechanism, a holder for the handle, and a separate stand to accommodate the bottle containing the irrigation fluid.




Figure 1: Main body

4.2. Handle

The ceramic plates within the handle experience an electric field generated by an external generator, causing them to alter their volume and produce ultrasonic vibrations.

4.3. Inserts

The different inserts available are given in Figure 3 and Figure 4

A Morphological – functional classificati

- Sharp tips -cuttin
- Diamond coated tips – abrasive

1. Rounded tips – Smoothing

B. Clinical classification

The clinical classification of piezosurgery tip is given in the Table 1.

There are two operating modes on the display: Bone and Root operating modes.

The former is assigned for cutting bone according to its density(type) and the latter is assigned to debride, shape, and refine the root surface. Within the bone mode, quality 1



Figure 2: Handle



Figure 3: Piezo inserts



Figure 4: Piezo inserts

Table 1: Clinical classification of inserts

| | |
|--------------------------|---|
| Osteotomy | OT1-OT2-OT3-OT4-OT5-OT6-OT7-OT8-OT9-OT10-OT11-OT12-OT13-OT14-OT15-OT16-OT17-OT18-OT19-OT20-OT21-OT22-OT23-OT24-OT25-OT26-OT27-OT28-OT29-OT30-OT31-OT32-OT33-OT34-OT35-OT36-OT37-OT38-OT39-OT40-OT41-OT42-OT43-OT44-OT45-OT46-OT47-OT48-OT49-OT50-OT51-OT52-OT53-OT54-OT55-OT56-OT57-OT58-OT59-OT60-OT61-OT62-OT63-OT64-OT65-OT66-OT67-OT68-OT69-OT70-OT71-OT72-OT73-OT74-OT75-OT76-OT77-OT78-OT79-OT80-OT81-OT82-OT83-OT84-OT85-OT86-OT87-OT88-OT89-OT90-OT91-OT92-OT93-OT94-OT95-OT96-OT97-OT98-OT99-OT100 |
| Osteoplasty- | OP1-OP2-OP3-OP4-OP5-OP6-OP7 |
| Extraction | EX1- EX2- EX3 |
| Implant site preparation | IM 1 – IM2A -IM2P- OT4- IM3 A- IM3P |
| Periodontal surgery | PS2-OP5-OP3-PP1 |
| Endodontic surgery | OP3-PS2-EN1-EN2-OP7 |
| Sinus Lift | OP3 -OT-EL1-EL2-EL3 |
| Ridge expansion | OT7– OT7S4-OP5-IM2-OT4-IM3 |
| Bone grafting | OT7- OT7S4-OP1-OP5 |
| Orthodontic | OT7S4-OT7S3 |
| Microsurgery | |

mode is suited for cutting and removing small fragments of cortical bone, while quality 2 mode is designed for smooth spongy/cancellous bone tissue. Two programmes in the root operating mode are the endo and the perio program. The endo program is for retrocanal /intracanal debridement after RCT whereas the perio program is for scaling, debridement and root planing.

5. Advantages

1. Piezosurgery is more efficient in the first phases of bone healing
2. Selective cutting
3. Minimal operative invasion
4. Greater control of device
5. There is faster bone regeneration and healing
6. Decreased traumatic stress
7. Decrease postoperative pain

6. The Risk of Emphysema is Low

In their 2008 study, Maurer et al. conducted a quantitative analysis of surface roughness in osteotomized bone surfaces prepared using both conventional osteotomy and the piezoelectric technique. Their findings suggested that the ultrasonic technique, particularly piezo-osteotomy, effectively preserved the original bone structure. Moreover, they observed that the superficial roughness was minimal in the piezo-osteotomy surface compared to surfaces prepared with microsaw and Lindeman bur osteotomy techniques.⁷

A study conducted by Schaeren and colleagues in 2008 revealed that even prolonged contact for up to 5 seconds between Piezosurgery inserts and a peripheral nerve did not dissect the nerve.⁸ Studies indicate that subjecting bone tissues to low-intensity, high-frequency vibrations ranging from 10 to 50 Hz mimics mechanical loading. This stimulation prompts the release of various growth factors, including bone morphogenetic proteins (BMPs), which play a crucial role in osteoblast differentiation

and the formation of new bone. (Li M et al. in 2015) Preti G et al., in a 2007 animal study, conducted a comparative analysis of the biomolecular profile of sites prepared using piezoelectric bone surgery versus rotary drills. The study showed a hike in BMP-4 in the early stage of post implant preparation done with piezoelectric unit and proinflammatory cytokine tumor necrosis factor alpha, proinflammatory and bone-resorbing cytokine interleukin-1 β (IL1 β), and antiinflammatory cytokine IL-10 were higher in the early experimental phases of drilled sites.⁹

Stoetzer M et al., in 2014 did a study at the biomolecular level and found that expression of collagen (II and IV) and osteocalcin in the 8 days following surgery was significantly greater at Piezosurgery-treated sites, thus indicating a more robust healing response.¹⁰ In a study by Goyal (2012), the comparison between piezosurgery and traditional rotary surgical methods revealed significant reductions in patient symptoms like pain, swelling, trismus, and improved healing outcomes at the piezosurgery site.¹¹ Additionally, a systematic review and meta-analysis conducted by Jiang et al. in 2015 examined the disparities between piezosurgery and conventional rotary approaches during third molar extraction. Their conclusion highlighted that despite the longer duration of surgery experienced by patients undergoing piezosurgery, they exhibited reduced swelling, less postoperative pain, and diminished postoperative trismus compared to other techniques.¹²

The meta-analysis performed by Al-Moraissi et al. in 2015 demonstrated a notable decrease in postoperative complications (such as facial swelling, pain, and trismus) associated with the use of piezosurgery in surgical extraction of the third molar. Conversely, their findings indicated that the surgical time for third molar extraction were significantly shorter when using conventional rotary instruments.¹³

7. Disadvantages

1. Time-consuming
2. Increased cost as compared with motor driven/manual instruments
3. Irrigation is essential to avoid overheating
4. Technology is difficult to learn

Stelzle et al. (2014) emphasized that increasing the applied load on the handpiece could accelerate the preparation speed; however, it may also amplify the adverse thermal effects on the bone.¹⁴

7.1. Contraindication

Piezosurgery is contraindicated in cases where either the patient/ operator has an electrical pacemaker. Age factor is a relative contraindication for piezosurgery procedures.

8. Applications

8.1. In oral and maxillofacial surgery

The application of piezosurgery in maxillofacial surgery ranges from atraumatic third molar extraction, enucleation of cysts and tumors, bone harvesting to alveolar distraction osteogenesis, surgical osteotomy and osteoplasty procedures, orthognathic surgery, TMJ ankylosis resection, jaw resection, removal of osteosynthetic materials like callus around mini-plates and screws.

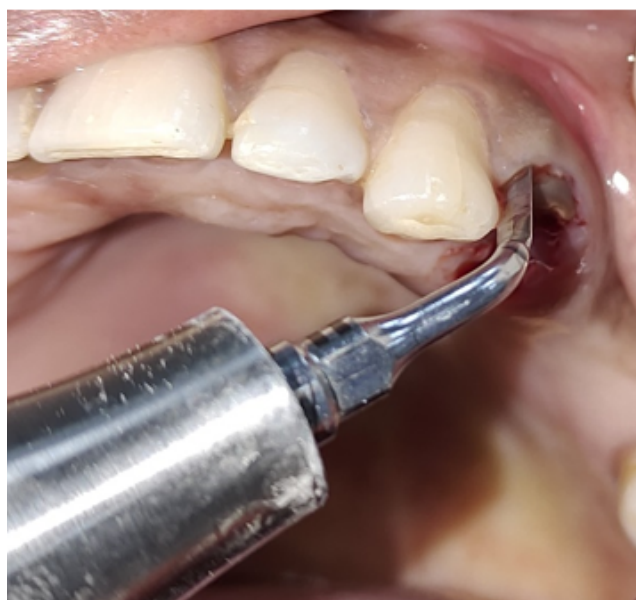

Figure 5: Atraumatic extraction

8.2. In endodontics

Piezosurgery is used in endodontics for hemisection, root amputation, apical resection and root canal treatment.

8.3. In Orthodontic surgery

Microsurgery, osteotomy, and corticotomy can be done with a piezosurgery unit.

8.4. In periodontics

Piezosurgery can be used in the field of Periodontics in scaling and root planing, crown lengthening, osteotomy, and osteoplasty procedures, soft tissue debridement during flap surgery, pocket elimination surgery, bone grafting of intrabony defects, implant site preparation, alveolar ridge splitting and expansion, recontouring of alveolar crest, bone harvesting, mental nerve repositioning, maxillary sinus lift, extraction for immediate implant positioning.

Supragingival and subgingival scaling: The tips are positioned vertically alongside the tooth's length

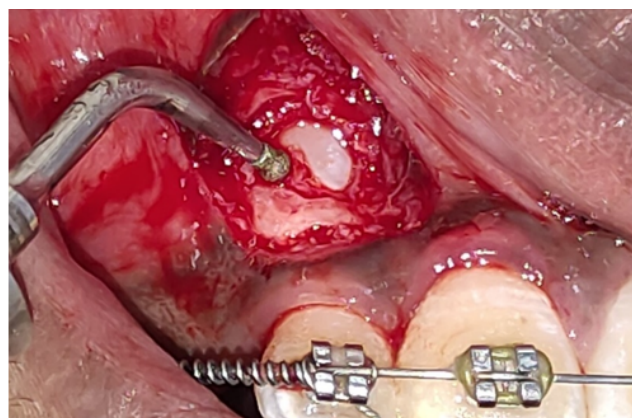


Figure 6: Exposure of impacted canine

and steadily move to eliminate both supragingival and subgingival calculus, debris and discoloration

Curettage: This device is employed for debriding the epithelial lining of the periodontal pocket, resulting in microcauterization.

Crown lengthening: Crown lengthening involves the precise reduction of bone (typically 1 to 2 mm) circumferentially around the tooth, coupled with osteoplasty. This process enables the placement of an apically positioned periodontal flap promoting a favorable architecture of the periodontal tissues. Performing osteotomy in challenging proximity scenarios with a Piezosurgery device (utilizing the Piezosurgery OP3 insert) is simplified due to precise maneuverability of the instrument. Furthermore, PP1 insert (blunt inserts) is found to be highly effective in root planing. A histologic animal study conducted at Harvard University in Cambridge, Massachusetts, showed a better healing response for bone and root cementum in teeth that were crown lengthened using Piezosurgery as compared to that with traditional rotary instruments.¹⁵

8.4.1. Resective osseous surgery

The initial flap can be elevated using a PS2 insert (scalpel-shaped) or OP 3 insert (rounded scalpel-like insert), facilitating the elevation of the secondary flap and the removal of granulation tissue. Top of Form Specialized diamond-coated tips are utilized to debride interproximal bony defects, aiding in comprehensive cleaning procedures. The coupling of ultrasonic microvibrations and cavitations produced by irrigation fluid eradicate toxins, dead cells, bacteria, and debris, which creates a clear physiology for healing. Veradi et al. in 2017 did a patient-based comparison of traditional instruments and Piezoelectric bone surgery in Resective Osseous surgery and concluded that piezosurgery is safe and shown to improve several healing parameters for patients.¹⁶

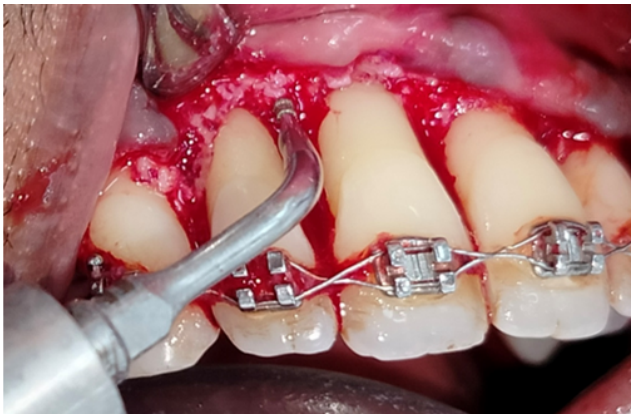


Figure 7: Resective osseous surgery

8.4.2. Bone harvesting

A. Bone Chips: Bone chips play a crucial role in creating space and providing guidance for regeneration of bone via osteoconduction. They also serve as a scaffold for growth factors at the recipient site, expediting bone healing. Bone chips can be harvested using Osteoplasty No. 1, 2 and 3 tips, employing delicate scratching movements along the bone surface

B. Bone blocks: The classic donor areas for bone blocks are the chin, linea obliqua and crista iliaca. With the use of piezosurgery, the linea obliqua technique has been simplified. The benefits of piezosurgery, like minimal vibration of the instrument tip, the efficient cooling effect and the precision cut, ensure minimal damage to the neighbouring structure.

Sohn et al. in 2007 compared piezoelectric bone surgery with conventional surgical burs/saws for procuring intraoral bone blocks and revealed that Piezosurgery unit developed an effective bone cuts with minimal or no injury to soft tissue.¹⁷ It had an immense effect in alleviating the distress and anxiety during a surgical procedure.

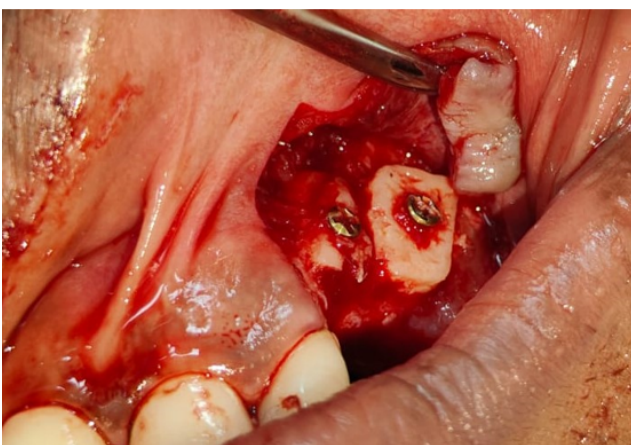


Figure 8: Block bone graft harvested using piezosurgery device

8.4.3. Dental implant surgery

In implant surgery, the piezosurgery unit has wide applications, including implant osteotomy preparation, alveolar ridge splitting and expansion before implant placement, recontouring of alveolar crest, nerve transposition - mental nerve repositioning, sinus lift procedures, implant removal, Lefort I osteotomy, relocation of malposed implants, peri-implantitis and calculus removal, removal of dental implants.

Arajji et al. conducted a randomized controlled clinical trial in 2023 comparing piezosurgery to conventional drills for implant site preparation. Their study assessed operation duration, implant stability, and bone density. Results indicated that the piezoelectric drilling method for implant site preparation appeared to be a dependable and consistent technique.¹⁸

A. Bone splitting

In cases with insufficient bone width and sufficient bone height, bone splitting may be indicated. In piezosurgery, an incision is made with a osteoplasty No. 5 (saw like). The osteotomes can be employed to expand the bone and implants can be positioned using a combination of drilling and splitting techniques. The bone fragments generated during drilling are appropriate for filling the gaps between the two lamellae. The suture needs no membranes and it should be tension free.

Majewski et al. in 2014 did studies with Piezosurgery device to obtain the accurate shape of block for augmenting a ridge defect and to secure it firmly in the recipient site. The piezosurgery in split crest procedures with immediate implant placement demonstrated an overall success rate of 97.2 with no risk of thermonecrosis, minimum risk of soft tissue alteration and satisfactory bone cutting efficiency.¹⁹

B. Sinus lift

Sinus augmentation is widely recognized as the preferred method to enhance bone volume in the posterior maxilla for implant placement. There's a notable risk of membrane perforation during the window preparation or elevation process. While piezosurgery tends to take more time compared to alternative techniques, it generally results in fewer instances of membrane perforation. Wallace et al. documented a mere 7 occurrences of membrane perforation out of 100 cases in their 2007 study employing piezosurgery.²⁰ In situations where the lateral wall is delicate, the diamond ball smoothing insert is applied. Conversely, on a thicker wall, it's more efficient to initially decrease its thickness using an OP insert before fine-tuning the window with the diamond-coated smoothing insert. The loss of bone tissue is generally lower with piezosurgery during sinus lift (Eggers et al; 2004). Vercellotti in 2001 reported in a study of patients who had 21 piezoelectric osteotomies, of which 95% were successful.²¹ Claudio Stacchi assessed two distinct methods for reducing cortical wall thickness in sinus floor augmentation surgery. Both

surgical approaches emerged as effective options for conducting lateral antrostomies during sinus floor elevation procedures, offering safety and predictability.²²

C. Inferior alveolar nerve positioning:

Bovi in 2005 was the first to reposition IAN using ultrasonic osteotomy and reported an improved surgical technique, reducing the risk of nerve injury, especially mental nerve.²³

D. Implant Site Preparation:

There are special Piezosurgery inserts developed for bone perforation which enabled the development of a newer technique for ultrasonic implant site preparation (UISP). The first advantage of UISP is the differential preparation of the cortical and cancellous bone. The *Differential implant site preparation* (DISP) technique can be used within the initial osteotomy site to correct the implant axis by selectively directing the cutting action in the desired direction. DISP can also be used in combination with twist drills to facilitate preservation of alveolar crestal bone while achieving maximum primary stability. The next advantage of UISP is the fast clinical healing of both soft and hard tissue. A histomorphometric study on mini-pigs showed more bone formation and a greater density of periimplant osteoblasts at implant sites prepared with Piezosurgery when it was compared with sites prepared with twist drills.⁹

E. REX PiezoImplant

It is the first implant exclusively placed with PIEZOSURGERY® in 2019. This new implant has an innovative wedge-shaped form and is inserted into a rectangular site that perfectly matches the anatomy of the residual ridge and thereby preserving vascularisation and protecting the vestibular bone size. This showed low morbidity and positive short-term clinical results in narrow ridge treatment with 98.3% survival rate.²⁴

9. Conclusion

Piezosurgery represents a contemporary surgical technique for bone surgery, showcasing numerous clinical applications within the field of dentistry. This innovative bone cutting system shows great potential, boasting exceptional precision and safety. It operates on ultrasonic micro vibrations meticulously calibrated to exclusively target mineralized tissue while safeguarding soft tissue and vital structures. The instrument's accuracy facilitates precise and seamless surgical incisions, offering significant assistance in conducting meticulous bone surgery. Consequently, piezosurgery possesses the capability to enhance treatment effectiveness while enhancing postoperative healing. Additionally, it has the capacity to redefine the minimally invasive concept in osseous surgery, thus replacing conventional techniques.

10. Source of Funding

None.

11. Conflicts of Interest


None.

References

- Vercellotti T. Technological characteristics and clinical indications of piezoelectric bone surgery. *Minerva Stomatol.* 2004;53:207–221.
- Mcfall TA, Yamane GM, Burnett GW. Comparison of cutting effect on bone of ultrasonic cutting device and rotary burs. *J Oral Surg.* 1961;19:200–209.
- Horton JE, Tarpley TM, Jacoway JR. Chapel Hill NC. Clinical applications of ultrasonic instrumentation in the surgical removal of bone. *Oral Surg Oral Med Oral Pathol.* 1981;51:236–278.
- Torrella F, Pitarch J, Cabanes G, Aniuta E. Ultrasonic osteotomy for surgical approach of maxillary sinus: A technical note. *Int J Oral Maxillofac Implants.* 1998;13:697–700.
- Vercellotti T. Piezoelectric surgery in implantology: A case report - A new piezoelectric ridge expansion technique. *Int J Periodont Restorative Dent.* 2000;20:359–65.
- Crosetti E, Battiston B, Succo G. Piezosurgery in head and neck oncological and reconstructive surgery: Personal experience on 127 cases. *Acta Otorhinolaryngol Ital.* 2009;29:1–9.
- Maurer P, Kriwalsky MS, Veras B, Vogel R, Syrowatka J, Heiss F, et al. *Clin Oral Implants Res.* 2008;19:570–575.
- Schaeren S, Jaquíry C, Heberer M, Tolnay M, Vercellotti T, Martin I. Assessment of nerve damage using a novel ultrasonic device for bone cutting. *J Oral Maxillofac Surg.* 2008;66(3):593–599.
- Preti G, Martinasso G, Peirone B, Navone R, Manzella C, Muzio G, et al. Cytokines and growth factors involved in the osseointegration of oral titanium implants positioned using piezoelectric bone surgery versus a drill technique: a pilot study in minipigs. *J Periodontol.* 2007;78(4):716–738.
- Stoetzer M, Magel A, Kampmann A. Subperiosteal preparation using a new piezoelectric device: a histological examination. *GMS Interdiscip Plast Reconstr Surg DGPW.* 2014;3:18–18.
- Goyal M, Marya K, Jhamb A, Chawla S, Sonoo PR, Singh V, et al. Comparative evaluation of surgical outcome after removal of impacted mandibular third molars using a Piezotome or a conventional handpiece: a prospective study. *Br J Oral Maxillofac Surg.* 2012;50(6):556–61.
- Jiang Q, Qiu Y, Yang C, Yang J, Chen M, Zhang Z. 2015.
- Al-Moraissi EA, Elmansi YA, Al-Sharaee YA, Alrmali AE, Alkhatari AS. Does the piezoelectric surgical technique produce fewer postoperative sequelae after lower third molar surgery than conventional rotary instruments? A systematic review and meta analysis. *International Journal of Oral and Maxillofacial Surgery.* 2016;45(3):383–391.
- Stelzle F, Frenkel C, Riemann M, Knipfer C, Stockmann P, Nkenke E. The effect of load on heat production, thermal effects and expenditure of time during implant site preparation - an experimental vivocomparison between piezosurgery and conventional drilling. *Clinical Oral Implants Research.* 2012;25(2):140–148.
- Vercellotti T, Nevins ML, Kim DM, Nevins M, Wada K, Schenk RK, et al. Osseous response following resective therapy with piezosurgery. *Int J Periodontics Restorative Dent.* 2005;25(6):543–552.
- Verardi S, Pastagia J. Patient-Based Comparison of Traditional Instruments and Piezoelectric Bone Surgery in Osseous Resective Surgery. *Int J Periodontics Restorative Dent.* 2017;37(3):433–440.
- Sohn DS, Ahn MR, Lee WH. Piezoelectric osteotomy of intraoral harvesting of bone blocks. *Int J Periodontics Restorative Dent.* 2007;27:3–7.
- Arakji H, Osman E, Aboelsaad N. Evaluation of implant site preparation with piezosurgery versus conventional drills in terms of operation time, implant stability and bone density (randomized controlled clinical trial- split mouth design). *BMC Oral Health.* 2022;22:567–567.

19. Majewski P. Autogenous bone grafts in the esthetic zone: optimizing the procedure using piezosurgery. *Int J Periodontics Restorative Dent.* 2014;34:355–363.
20. Wallace SS, Mazor Z, Froum SJ, Cho SC, Tarnow DP. Schneiderian membrane perforation rate during sinus elevation using piezosurgery: clinical results of 100 consecutive cases. *Int J Periodontics Restorative Dent.* 2007;27(5):413–422.
21. Vercellotti T, Paoli D, Nevins S, M. The piezoelectric bony window osteotomy and sinus membrane elevation: introduction of a new technique for simplification of the sinus augmentation procedure. *Int J Periodontics Restorative Dent.* 2001;.
22. Stacchi C, Lombardi T, Cusimano P, Berton F, Lauritano F, Cervino G, et al. Bone Scrapers Versus Piezoelectric Surgery in the Lateral Antrotomy for Sinus Floor Elevation. *J Craniofac Surg.* 2017;28(5):1191–1196.
23. Bovi M. Mobilization of the inferior alveolar nerve with simultaneous implant insertion: a new technique. Case report. *Int J Periodontics Restorative Dent.* 2005;25(4):375–83.
24. Vercellotti T, Troiano G, Oreglia F, Lombardi T, Gregorig G, Morella E. Wedge-Shaped Implants for Minimally Invasive Treatment of Narrow Ridges: A Multicenter Prospective Cohort Study. *JCM.* 2020;9(10):3301–3301.

Author biography

Aswathy Jayasree, PG Student  <https://orcid.org/0009-0007-5020-6110>

Raseena Beevi, Professor  <https://orcid.org/0000-0003-1008-5418>

Roshni Ramesh, Professor

Ajith Kumar K C, Associate Professor

Shruthi Reghunath, PG Student

Bilha Joy, PG Student

Abdurasheed E M, PG Student

Cite this article: Jayasree A, Beevi R, Ramesh R, Ajith Kumar K C, Reghunath S, Joy B, Abdurasheed E M. Revolutionizing periodontal procedures: The potential of piezoelectric devices. *Arch Dent Res* 2024;14(1):20-27.