



Original Research Article

Ramus & gonial angle measurement in sexual dimorphism - A digital panoramic study

Priya Singh^{1*}, Updender Malik¹, Mysore K Sunil¹, Lakshya Vishnoi¹, Arpan Manna¹, Tanha Khan²

¹Dept. of Dentistry, Teerthanker Mahaveer Dental College and Research Centre, Uttar Pradesh, India
²Dept. of Oral Medicine and Radiology, Daswani Dental College, Kota, Rajasthan, India



ARTICLE INFO

Article history:

Received 10-07-2023

Accepted 03-11-2023

Available online 18-12-2023

Keywords:

OPG

Sexual Dimorphism

Ramus

Gonial Angel

ABSTRACT

Introduction: Age and sex must be determined for forensic practise and medico-legal objectives. The mandible, which is the most heterogeneous bone in the skull and is frequently found intact, may be a key component in sex assessment. In this regard, the availability of a large number of antemortem orthopantomograms may be very beneficial in researching and creating standards that are population-specific for precise sex and age determination. Determining the value of different mandibular ramus linear and gonial angle measures as sex and age markers on digital panoramic pictures was the goal of the current investigation.

Study Design: This retrospective study was conducted on 600 orthopantomogram of patients of both gender with age group of 18 to 50 years.

Materials and Methods: The selected JPEG images of the digital OPG's were converted to PDF format and exported to Adobe Acrobat Reader software on an HP Laptop for assessment of linear and angular measurements. The parameters employed in the current study were projective ramus height (PRH), condylar ramus height (CNRH), coronoid ramus height (CRRH), upper ramus breadth (URB), lower ramus breadth (LRB), bigonial width (BW) and gonial angle (GA).

Result: The right PRH, CRRH, CNRH, URB, LRB and bigonial width were higher in males as compared to females similarly left PRH, CNRH, CRRH, URB were higher in males as compared to females with a statistically significant P value (0.001) It was concluded from the current study that various parameters, including the projective ramus height, minimum ramus breath, and coronoid ramus height, could be very helpful in determining gender.

This is an Open Access (OA) journal, and articles are distributed under the terms of the [Creative Commons Attribution-NonCommercial 4.0 International](https://creativecommons.org/licenses/by-nc/4.0/), which allows others to remix, and build upon the work non-commercially, as long as appropriate credit is given and the new creations are licensed under the identical terms.

For reprints contact: reprint@ipinnovative.com

1. Introduction

Forensic odontology employs dental evidence to address issues pertaining to human identification. Gender determination marks the beginning of the identification process.¹⁻³

The rise in violent crimes and the amount of unidentified, mutilated corpses brought to the attention of forensic

experts have necessitated this kind of investigation. Sex, age, and ethnicity can be distinguished using both qualitative and quantitative criterias. Every person in the world has a unique identity, and FO places a high value in the identification of both living and dead people.^{3,4}

The mandible is the strongest bone. The coronoid and condyloid processes are located on the rami. The mandible is thought to be good for investigation because it is the most resilient bone and holds its shape better than other bones.^{4,5}

* Corresponding author.

E-mail address: arpanmanna97@gmail.com (P. Singh).

Sexual dimorphism of the mandible is influenced by genetic, hormonal and socioenvironmental factors such as food, nutrition, climate, masticatory forces and the presence of various pathologies. The results must be population specific even though several studies have used particular mandibular components.^{5–7}

OPG is a radiographic procedure that is readily available and is employed in dental practice which provides a bulge information.⁸ Thus, antemortem panoramic radiographs may be of immense value in establishing human identity. However, review of literature revealed a paucity of research related to combined linear and angular measurements of the rami and gonial angles on panoramic radiographs.^{8,9}

Considering the importance of mandible in sexual dimorphism this study was undertaken to evaluate the utility of both linear mandibular ramus dimensions and gonial angle measurements on digital panoramic images for gender determination in the North- Indian population with the aim to determine morphology of the mandibular ramus and gonial angle measurements on digital panoramic radiographs of dentate patients in the North Indian population and the objective to establish a correlation between mandibular ramus and gonial angle measurements with respect to gender and to find out the most reliable parameter with respect to gender determination.

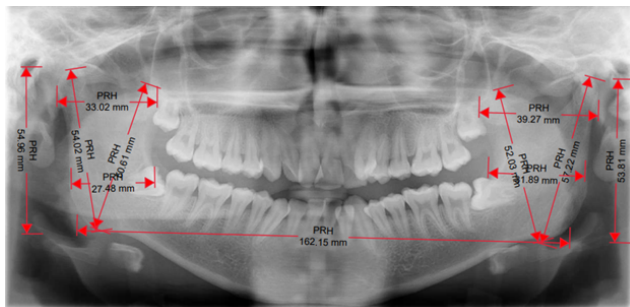


Figure 1: Showing bilateral measurements of ramus

2. Materials and Methods

The department of oral medicine and radiology conducted this retrospective study in TMDC&RC, the digital OPG radiographs were retrieved from the computer data base in the radiology department.

This retrospective study was conducted on 600 orthopantomogram of patients of both gender with age group of 18 to 50 years retrieved from the electronic data base from Radiology section of OMDR department, TMDCRC after being approved from the institutional ethical committee.

The images selected for the study were based upon the following inclusion and exclusion criteria:

2.1. Inclusion criteria

DPR of optimum quality and clearly depicting the mandibular ramus area.

2.2. Exclusion criteria

Pathologies affecting the posterior mandibular area of region the angle and ascending ramus region of the mandible were not included in the study.

Trauma, cyst, tumors and surgical procedures performed in the mandibular posterior region were excluded.

Completely edentulous arches of both maxilla and mandible regions.

2.3. Methodology

The selected JPEG images of the digital OPG's were converted to PDF format and exported to Adobe Acrobat Reader software on an HP Laptop for assessment of linear and angular measurements.

Linear measurements were performed using adobe acrobat reader according to the criteria adopted by Maloth K N et al. in the year 2017¹⁰ as under:

1. *Upper ramus breadth (URB)*: the distance between the most anterior to the most posterior point of the ramus passing through the sigmoid notch
2. *Lower ramus breadth (LRB)*: the distance between the most anterior to the most posterior point of the ramus at the level of the occlusion plane along a line parallel to the previous one

In order to achieve standardization, prior to marking the following (c to e), a horizontal orientation line was digitally traced passing through the summit of the gonial angle

1. *Condylar ramus height (CNRH)*: the distance from the condylion to the intersection of the orientation line with the inferior border of the ramus
2. *Projective ramus height (PRH)*: the projective distance between the condylion and the orientation line
3. *Coronoid ramus height (CRRH)*: the distance between coronion and the intersection of the orientation line with the inferior border of the ramus.

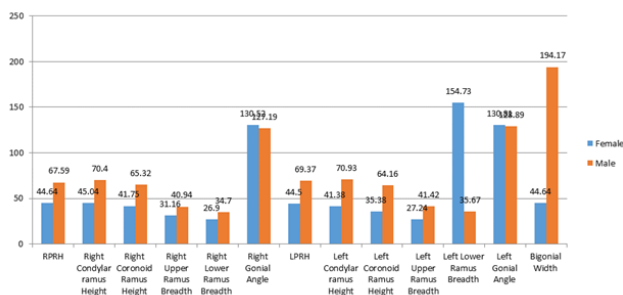
The angular measurements (Figure 1) were performed according to the criteria by Jambunath U et al. in the year 2016¹¹

1. *Gonial angles (GA)*: intersection of a line tangential to the most inferior points at the gonial angle and the lower border of the mandibular body and another line tangential to the posterior borders of the ramus and the condyle.
2. *Bigonial width (BW)*: the distance between both the gonion horizontally from the right to the left intersection of the orientation line with the inferior border of the ramus.

3. Results

The parameters employed in the current study were projective ramus height (PRH), condylar ramus height (CNNRH), coronoid ramus height (CRRH), upper ramus breadth (URB), lower ramus breadth (LRB), bigonial width (BW) and gonial angle (GA).

The right PRH, CRRH, CNRH, URB, LRB and bigonial width were higher in males as compared to females similarly left PRH, CNRH, CRRH, URB were higher in males as compared to females with a statistically significant P value (0.001) when subjected to independent student t – test, on the contrary, values of LGA and LLRB were more in females as compared to males with statistically significant P value (0.001) when subjected to independent student t- test as shown in Table 1.



Graph 1: Intergroup comparis

The discriminate functions at group centroids (group means) were -10.311 for males and 10.311 for females Accuracy of prediction-100%

RPRH+0.026 x RCNRH-0.041 x RCRRH+0.076 x RURB-0.017 x RLRB+

0.052 x RGA -0.064 x LPRH+0.032 x LCNRH+0.109 x LCRRH-0.118 x LURB+0.133 x LLRB-0.040 x LGA-0.034 x BW

The discriminate functions at group centroids (group means) were -10.311 for males and 10.311 for females As shown in Table 2.

4. Discussion

The first step in making an individual identity is gender determination, which is done after species identification of the human species. Adult male and female skeletons display various size and shape traits.^{12–14} This serves as the discipline's foundation. The size and shape of the mandible exhibit dimorphism. Mandibular ramus measurements typically exhibit higher levels of sexual dimorphism. The mandibular ramus exhibits gender differences more clearly than the mandibular body does. Accurate sex determination techniques are based on measurement and morphology.^{15–17} In the present study among 600 subjects of which 300 males and 300 females. The right projective ramus height

(RPRH) showed the (mean±SD) 67.59±12.130 in males whereas (mean±SD) 44.64±2.670 in female group which were significant and were with study done Samatha et al in the year 2016 and Maloth KN et al in 2017 which stated mandibular ramus height to be the best parameter and in their studies these parameters were larger for males than females.^{18–20}

Similarly, on the left projective ramus height (LPRH) also with the (mean±SD) 69.37 ±12.924 in males and in females with (mean±SD) 44.56 ±3.041 standard deviation which was statistically significant with value of 0.001, which was in accordance with the study done by Jambunath U et al in the year 2016.^{21–23}

The right condylar ramus height (RCNRH) showed higher mean value of about (mean±SD)70.40 ±13.639 than females and the left condylar ramus height also showed the higher mean values in males (mean±SD) 70.93 ±13.202 which was statistically significant with P value of 0.001 which was similar to the study done by Abu Taleb NS et al in the year 2015.^{24,25}

However the right coronoid ramus height and the left coronoid ramus height (CRRH) also showed higher mean measurement values in males of (mean±SD) 65.32±13.241 and (mean±SD) 64.16 ±12.489. The right and left coronoid ramus height also showed significant values with the P value of 0.001 which was higher in males than females which was in agreement with the study done by and Maloth KN in the year 2017.^{23,26}

The right and left upper ramus mean measurements were more in males (mean±SD) 40.94 ±8.373 and on left side it is predominant in males with (mean±SD) 41.42±8.019 which was statistically sig. with P val. of 0.001 respectively which was in similar with the study done -Indira AP et al. in the year 2012 and Mostafa RA et al. year 2020.^{27,28}

But a significant difference was observed between the right and left sides of the lower ramus breadth in both the genders in which values were more in male group on right side (mean±SD) 34.70± 7.172 and in females the values were predominant in lower ramus breadth on left side (mean±SD) 154.73± 10.235 with P val. Which was alike to the work by Sharma M et al. at 2015 and Damera A et al. year 2016.[24,28-29]^{24,28}

A statistically significant difference was noted in the right and left side of gonial angle among both the genders. The right and left gonial angle values were larger in female group with (mean±SD) 130.52± 5.662 and (mean±SD) 30.81 ±4.679 than males with mean (mean±SD) 127.19 ± 5.648 and (mean±SD) 128.89 ±5.75 with p value of 0.001 which was in accordance with the studies done by Abu Taleb NS in the year 2015, Abuhijleh E et al. in the year 2019 and Leversha J et al. in the year 2016. Males have a larger ramus height and bigonial width than females.²⁸

The bigonial width were predominantly higher in males with (mean±SD) of 194.17±35.621 with than females with

Table 1: Intergroup comparison of all parametres

	Gender	Mean	Std. Deviation	Std. Error Mean	P value
RPRH	Female	44.64	2.670	0.154	0.001 (Sig)
	Male	67.59	12.130	0.700	
Right Condylar ramus Height	Female	45.04	2.369	0.136	0.001 (Sig)
	Male	70.40	13.639	0.787	
Right Coronoid Ramus Height	Female	41.75	4.193	0.242	0.001 (Sig)
	Male	65.32	13.241	0.764	
Right Upper Ramus Breadth	Female	31.16	2.514	0.145	0.001 (Sig)
	Male	40.94	8.373	0.483	
Right Lower Ramus Breadth	Female	26.90	3.109	0.179	0.001 (Sig)
	Male	34.70	7.172	0.414	
Right Gonial Angle	Female	130.52	5.662	0.326	0.001 (Sig)
	Male	127.19	5.648	0.326	
Bigonial Width	Female	44.64	2.126	0.122	0.001 (Sig)
	Male	194.17	35.621	2.056	
LPRH	Female	44.50	3.041	0.175	0.001 (Sig)
	Male	69.37	12.924	0.746	
LCNRH	Female	41.38	3.215	0.185	0.001 (Sig)
	Male	70.93	13.202	0.762	
LCRRH	Female	35.38	7.154	0.413	0.001 (Sig)
	Male	64.16	12.489	0.721	
LURB	Female	27.24	2.812	0.162	0.001 (Sig)
	Male	41.42	8.019	0.463	
LLRB	Female	154.73	10.235	0.590	0.001 (Sig)
	Male	35.67	7.719	0.445	
LGA	Female	130.81	4.679	0.270	0.001 (Sig)
	Male	128.89	5.75	0.332	

Table 2: Stepwise discriminant function analysis equation for sex prediction–Based on All Measurements

Sex	Predicted Group Membership		Total
	Male	Female	
Male	300 (100.0%)	0 (0.0%)	300
Female	0 (0.0%)	300 (100.0%)	300

(mean±SD) of 44.64 ±2.126. This resembled the research conducted by Leversha J et al. in the year 2016.

All parameters were statistically significant hence each variable was significant predictor in classifying the gender. All parameters have higher male measurements except left lower ramus breadth and gonial angle the values of which were significantly higher in females.

Gender determination is the key in forensic odontology as it is mostly required for medico-legal purposes and for establishment of identity.

5. Conclusion

It was concluded from the current study that various parameters, including the projective ramus height, minimum ramus breath, and coronoid ramus height, could be very helpful in determining gender. Mandibular ramus linear measurements from the condyle in selected North Indian populations demonstrated stronger sexual dimorphism in relation to gender as they were connected to the

largest dimorphic morphological change in size during remodelling. Further, multicentric studies with larger sample size and ethnic variability are needed to further strengthen the observations in the present study.

6. Source of Funding

None.

7. Conflict of Interest

None.

References

- Mostafa RA, Ej-Fotouh MA. Mandibular morphometric analysis for sex assessment: A retrospective radiographic study. *J Indian Acad Oral Med Radiol.* 2020;32(3):266–70.
- Taleb NSA, Beshlawy ME. Mandibular Ramus and Gonial Angle Measurements as predictors of sex and age in an Egyptian population sample. A digital panoramic study. *J Forensic Res.* 2015;6(5):1–7.

3. Sperber GH. Current concepts in embryonic craniofacial development. *Crit Rev Oral Biol Med.* 1992;27(4):67–72.
4. Behl AB, Grewal S, Bajaj K, Baweja PS, Kaur G, Kataria P, et al. Mandibular ramus and gonial angle - Identification tool in age estimation and sex determination. A digital panoramic radiographic study in North- Indian population. *J Indian Acad Oral Med Radiol.* 2016;8(2):31–7.
5. Poongodi V, Kanmani R, Kannan AAM, Raghuram PH. Prediction of age and gender using digital radiographic method: A retrospective study. *J Pharm Bio all Sci.* 2015;7(2):504–12.
6. Apaydin BK, Ozbey H. Radiographic evaluation of mandibular morphometric differences in prepubertal and postpubertal individuals in a Turkish subpopulation. *SRM J Res Dent Sci.* 2020;11(1):16–20.
7. Sharma M, Gorea RK, Gorea A, Abuderman A. A morphometric study of the human mandible in the Indian population for sex determination. *Egyptian J Forensic Sci.* 2016;6(2):165–9.
8. Leversha J, Welsh J, Keough G, Murteza A, Wakefiled HS, et al. age and gender correlation of gonial angle, ramus height, and bigonial width in dentate subjects in a dental school in Far North Queensland. *J Clin Exp Dent.* 2016;8(1):49–54.
9. Maloth KN, Kundoor VK, Vishnumolakala SL, Kesidi S, Lakshmi MV. M Mandibular ramus: a predictor for sex determination - A digital radiographic study. *J Indian Acad Oral Med Radiol.* 2017;29:242–8.
10. Jambunath U, Balaji PG, Poornima C, Latha S. ormer sex determination by using mandibular ramus and gonial angle - a preliminary comparative study. *Int J Contemp Med Reserve.* 2016;3(11):3278–80.
11. Damera A, Mohanalakshmi J, Yellarthi PK, Rezwana BM. Radiographic evaluation of mandibular ramus for rnama gender estimation: Retrospective study. *J Forensic Dent Sci.* 2016;8(2):74–82.
12. Raj JD, Ramesh S. Sexual dimorphism in mandibular ramus of south Indian population. *Antrocom Online J Anthropol.* 2013;9(2):253–8.
13. Huuonen S, Sipilä K, Haikola B, Tapio M, Raustiaam, Söderholm AL. Influence of edentulousness on gonial angle, ramus and condylar height. *J Oral Rehabil.* 2010;37(1):34–8.
14. Kşayan R, Aktan AM, Sökücü O, Haştar E, Ciftci ME. Does the panoramic radiography have the power to identify the gonial angle in orthodontics? *Sci World J.* 2012;p. 219708. doi:10.1100/2012/219708.
15. Kitai N, Mukai Y, Murabayashi M, Kawabata A, Washino K, Matsuoka M. Measurement accuracy with a new dental panoramic radiographic technique based on tomosynthesis. *Angle Orthod.* 2013;83(1):117–43.
16. Mattila K, Altonen M, Haavikko K. Determination of the gonial angle from the orthopantomogram. *Angle Orthod.* 1977;47(2):107–17.
17. Larheim TA, Svanaes DB. Reproducibility of rotational panoramic radiography: mandibular linear dimensions and angles. *Am J Orthod Dentofac Orthop.* 1986;90(1):45–51.
18. Nohadani N, Ruf S. Assessment of vertical facial and dentoalveolar changes using panoramic radiography. *Eur J Orthod.* 2008;30:262–70.
19. Shahabi M, Ramazanzadeh BA, Mokhber N. Comparison between the external gonial angle in panoramic radiographs and lateral cephalograms of adult patients with Class I malocclusion. *J Oral Sci.* 2009;51(3):425–34.
20. Ogawa T, Osato S, Shishido Y, Okada M, Misaki K. Relationships between the gonial angle and mandibular ramus morphology in dentate subjects: a panoramic radiophotometric study. *J Oral Implantol.* 2012;38(3):203–10.
21. Upadhyay RB, Upadhyay J, Agrawal P, Rao NN. Analysis of gonial angle in relation to age, gender, and dentition status by radiological and anthropometric methods. *J Forensic Dent Sci.* 1999;4(1):883–91.
22. Raghavan R, Sidhu SS, Kharbanda OP. Craniofacial pattern of parents of children having cleft lip and/or cleft palate anomaly. *Angle Orthod.* 1994;64(2):137–81.
23. Sağlam AA. The vertical heights of maxillary and mandibular bones in panoramic radiographs of dentate and edentulous subjects. *Quintessence Int.* 2002;33:433–441.
24. Dutra V, Yang J, Devlin H, Susin C, Rai R, Ranade AV, et al. A pilot study of the mandibular angle and ramus in Indian population. *Int J Morphol.* 2007;25(2):353–9.
25. Alshamout R, Ammouh M, Alrbata R, Alhabbah A. Age and gender differences in gonial angle, ramus height and bigonial width in dentate subjects. *Pak Oral Dental J.* 2012;32.
26. Singh R, Mishra SR, Singh S, Passey J, Kumar P. Sexual dimorphism in adult human mandible of north Indian origin. *Forensic Med Anat Res.* 2015;3(3):82–90.
27. Schulze R, Krummenauer F, Schalldach F, Hoedt B. Precision and accuracy of measurements in digital panoramic radiography. *Dentomaxillofac Radiol.* 2000;29(1):52–6.
28. Roman GG, Lukas D, Beniashvili R, Schulte W. Areadependent enlargement ratios of panoramic tomography on orthograde patient positioning and its significance for implant dentistry. *Int J Oral Maxillofac Implants.* 1999;14(2):248–57.

Author biography

Priya Singh, -

Updender Malik, Professor

Mysore K Sunil, Professor & Head

Lakshya Vishnoi, -

Arpan Manna, - <https://orcid.org/0000-0001-8787-3952>

Tanha Khan, Senior Lecturer <https://orcid.org/0009-0001-1147-2594>

Cite this article: Singh P, Malik U, Sunil MK, Vishnoi L, Manna A, Khan T. Ramus & gonial angle measurement in sexual dimorphism - A digital panoramic study. *Arch Dent Res* 2023;13(2):100-104.