



Case Report

Stafne bone cyst of mandible: A case report with comprehensive imaging features using cone beam computed tomography and literature review

Komal Deotale^{1*}, Ashish Lanjekar¹, Isha Madne¹, Charwak Tayade¹, Zareesh Akhtar¹, Raksha Jaiswal¹

¹Dept. of Oral Medicine and Radiology, Swargiya Dadasaheb Kalmegh Smruti Dental College and Hospital, Nagpur, Maharashtra, India



ARTICLE INFO

Article history:

Received 12-12-2022

Accepted 14-01-2023

Available online 20-02-2023

Keywords:

Stafne Bone Cyst

Pseudocyst

Mandible

Unilocular radiolucency

Cone Beam Computed Tomography

ABSTRACT

Stafne's bone cyst (SBC) is a rare, asymptomatic, unilateral oval shaped radiolucent defect mostly in the posterior region of the mandible below the inferior alveolar canal. This report describes a case of SBC in Central Indian Population, which was an incidental finding in a 65-year old male patient who presented with pain. This article also highlights the literature, differential diagnosis along with use of various diagnostic imaging resources, imaging features and management for this bone defect and adds a new Indian case to literature.

This is an Open Access (OA) journal, and articles are distributed under the terms of the [Creative Commons Attribution-NonCommercial 4.0 International](https://creativecommons.org/licenses/by-nc/4.0/), which allows others to remix, and build upon the work non-commercially, as long as appropriate credit is given and the new creations are licensed under the identical terms.

For reprints contact: reprint@ipinnovative.com

1. Introduction

Stafne Bone Cyst (SBC) is defined as pseudocyst of the jaw. SBC was brought to light in 1942 by Edward Stafne. The prevalence ranges from 0.10% to 0.48%.¹ Most common in males. Male to female ratio is 6:1. Usually evident after 40 years of age.² It is thought to be a normal anatomical variation.³ Synonyms for SBC are as follows: "Stafne bone cavity", "latent bone cyst", "aberrant salivary gland defect", "developmental bone defect of the mandible", "idiopathic bone cavity", or "cortical mandibular depression". As it is a pseudocyst it is filled with salivary gland tissue, fat, blood vessels, lymphoid tissue, connective tissue, muscles, etc. Depression from hypertrophic lobe of salivary gland, vascular compression, incomplete fusion of Meckel's cartilage during ossification are some suggested etiological theories for SBC.⁴ SBC is an incidental finding found in usual plain radiographs that are taken for chief complaint of patient. If 3D imaging modalities are available then it can

be done in case of SBC for detailed evaluation. In general SBC is an asymptomatic, ovoid, unilocular, non-progressive radiolucency which do not require any treatment. However, periodic radiographic evaluation is necessary to assess any pathological and dimensional changes.³ We report a case of SBC in Central Indian population, which was an incidental finding in a 65-year old male patient who presented to department with pain due to Periapical abscess.

2. Case Report

A 65-year-old male patient, worker from Amar Nagar, reported to the Department Of Oral Medicine and Radiology on 28th August, 2022 with complaint of pain in lower left back region of jaw since 7 days. Patient was apparently alright 7 days back then he started experiencing pain in lower left back region of jaw which was mild and intermittent in nature. There was no history of any aggravating and relieving factor, no history of any associated swelling and no history of balm application. There was no relevant past medical or dental history.

* Corresponding author.

E-mail address: komaldeotale120@gmail.com (K. Deotale).

Patient had habit of kharra chewing 4-5 times a day, since 20 years. On extraoral examination face was bilaterally symmetrical, lips were competent, TMJ revealed bilateral synchronous movements with no clicking and lymph nodes were not palpable (Figure 1). On Soft tissue examination buccal mucosa, labial mucosa, hard palate, soft palate and floor of mouth were normal. Generalized gingival recession was present (Figure 2). Sinus tract was present on attached gingiva with respect to 36. Hard tissue examination revealed Proximal caries with 36, Tenderness on Percussion (TOP) +ve with 36; Grade III mobility with 42, 31 and 37, TOP -ve with 42, 31, 37; Missing 15, 16, 25, 32, 38, 41, 47, 48; Root piece with 24; Severe abrasion with 22 and 23; Generalized attrition; Stains +; Calculus++ (Figure 3). Based on the clinical findings Provisional Diagnosis of Apical periodontitis with 36; Localized periodontitis with 42, 31, 37 and Partially edentulous maxillary and mandibular arch was given. Periapical abscess with 36 was given as differential diagnosis. Patient was advised Intra Oral Periapical Radiograph with 36 region and was referred to Department of Endodontics with a final diagnosis of Chronic periapical abscess with 36. Patient was also prescribed with Antibiotic (Tab. Amoxclav 625 mg BD for 3 days), Analgesic (Tab. Zerodol SP BD for 3 days), Antacid (Tab Pan 40 OD for 3 days). Further the patient was referred back to the department for Cone Beam Computed Tomography (CBCT) with 36 region. CBCT revealed Radiolucency in coronal portion of 36 distally involving enamel, dentin and pulp suggestive of distal caries with 36; Loss of lamina dura with 36 and 37; Periapical radiolucency with mesial and distal root of 36 along with furcation involvement suggestive of periapical rarefying osteitis with 36; Attrition with 37; Periapical radiolucency with mesial and distal root of 37 along with furcation involvement suggestive of periapical rarefying osteitis with 37 (Figure 4). A localized, well-defined, unilocular radiolucency was also present below the mandibular canal and above the inferior border of mandible with thick sclerotic border (Figure 4); 11.93*7.68 mm in size (Figure 5); Localized to lingual cortical plate of mandible (Figure 6); Totally radiolucent (Figure 4); Roughly oval in shape (Figure 4) and was continuous to the mandible base (Figure 4). This incidental finding modified our final diagnosis to Chronic periapical abscess with 36; Localized periodontitis with 42, 31, 37; Partially edentulous maxillary and mandibular arch and Stafne bone cyst (Type II) on left side of mandible. Patient was recalled for follow up after every 6 months for evaluation of stafne bone cyst regarding any pathological involvement and changes in dimensions.

3. Discussion

Stafne bone cyst (SBC) is a radiolucent depression or defect in the mandible.⁴ The etiology of SBC remains unclear. Different theories suggest that SBC arises because

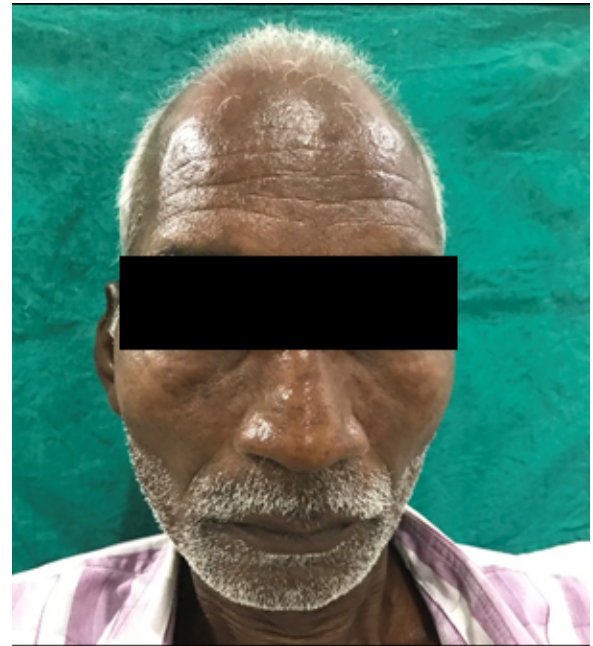

Figure 1: Extra oral profile of patient.

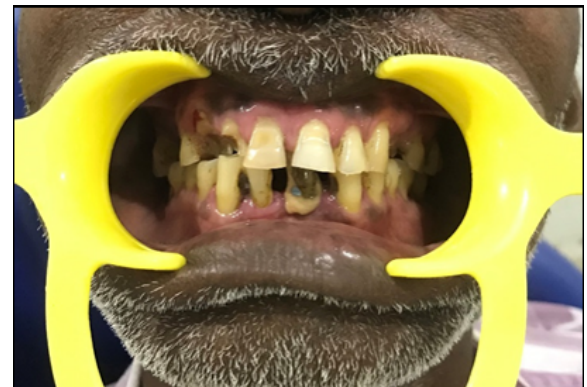

Figure 2: Generalized gingival recession.

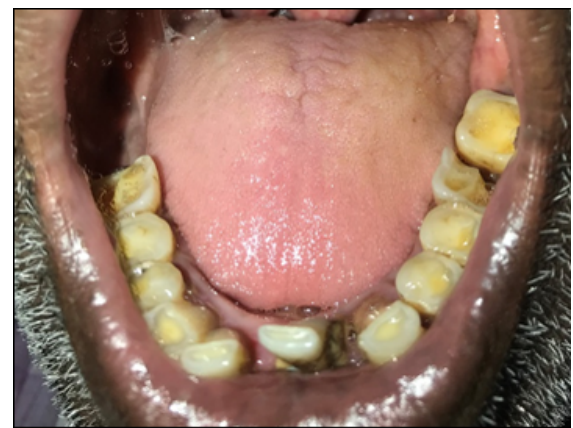

Figure 3: Intra oral picture showing condition of teeth in lower arch.

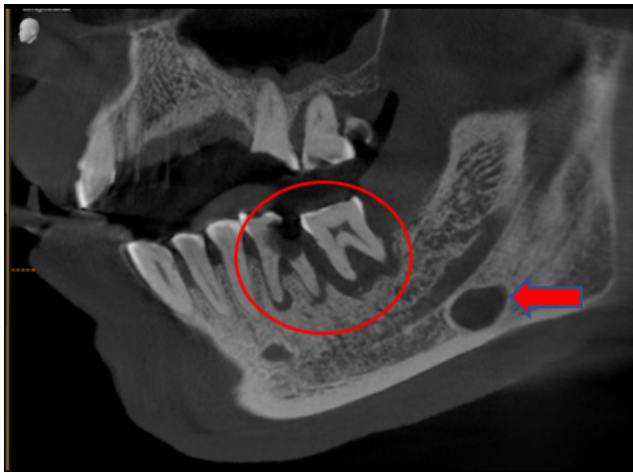


Figure 4: Longitudinal section of CBCT showing periapical pathology with 36, 37 and also showing an unilocular radiolucency involving body of mandible.




Figure 5: Greatest dimensions of the defect.

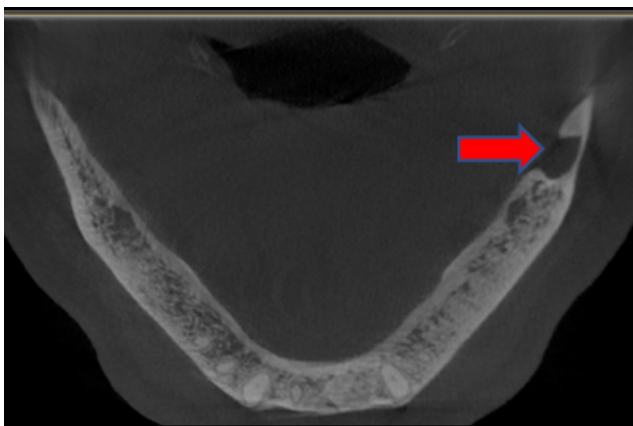


Figure 6: Axial section of CBCT showing radiolucency involving the lingual cortical plate of mandible.

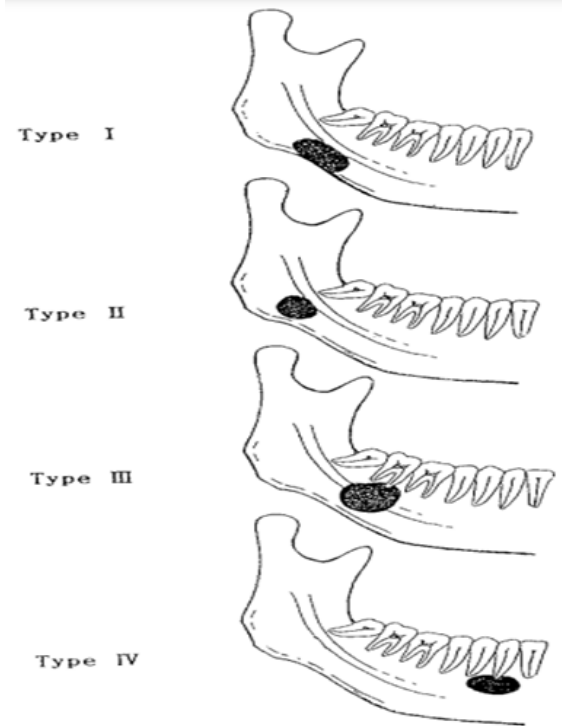


Figure 7: Radiographic classification of SBC by hisao shigematsu, tsutomu osuga and kuniya fujita. Table 1

a part of salivary gland becomes entrapped during the development of the mandible other theories suggest that local pressure of sublingual or submandibular salivary gland to the bone induces SBC. SBC's are asymptomatic bone lesions therefore cannot be usually detected clinically. Omur Dereci and Serpil Duran (2012) had found exposure of the defect into the oral cavity. SBC's are well-circumscribed ovoid radiolucent bone defects usually located lingually on the posterior mandible below the inferior alveolar canal as in this case.⁵ Lucas Morita et al(2021) in his study had found that SBC involves the left side of mandible more commonly than right side as seen in this case.⁶ Different investigations that can be done for SBC are as follows Orthopantomogram (OPG), Cone Beam computed Tomography (CBCT), Computed Tomography Scan (CT) and MRI (Magnetic Resonance Imaging). On panoramic radiograph SBC typically resembles a unilocular cystic lesion with well-defined borders although multilocular lesions are also evident. CT and CBCT scan has an advantage over OPG that possible assessment of cortical wall perforations and expansion can be done. MRI shows any soft tissue filling the defect and also helps to confirm the presence of salivary tissue on T2 and T1-weighted multiplanar imaging.⁴ The size of the SBC ranges from 0.8 cm to 3.8 cm.²

Table 1: Radiographic classification of SBC by hisao shigematsu, tsutomu osuga and kuniya fujita (1993)⁷

Type	Feature
Type I - Indentation Type	The inferior border of mandible is involved.
Type II - Medium Type	The radiolucency is located above the inferior border of mandible but below the mandibular canal.
Type III - Deviation Type	Deviation of mandibular canal.
Type IV - Anterior Type	The radiolucency is located in the anterior portion of mandible.

*Radiographic classification of SBC by Arijj et al. (1993)*⁸Figures 8, 9 and 10 — Radiographic classification of SBC by Arijj et al.



Figure 8: Type 1 — Defect at bottom does not reach the buccal cortex.



Figure 9: Type 2 - Defect at bottom does reaches the buccal cortex without its expansion.



Figure 10: Type 3 — Buccal expansion of cortical plate.

Table 2: 4 Topographical variants of SBD⁴

Variants	Features
Lingual Posterior	The defect is in the submandibular gland area, which is in the posterior region of the mandible.
Lingual Anterior	The defect is in the sublingual gland area, in the anterior mandible region, or in mandible body.
Lingual Ramus	The defect was in the parotid gland area, which is in the ramus of the mandible.
Buccal Ramus Depression	Buccal aspects of the ascending mandibular ramus.

The most frequently observed variant is the lingual posterior, typically located near the angle of the mandible and under the inferior alveolar canal on panoramic radiographs.

4. Radiographic Features of SBC.⁴

4.1. Margins

Margins of the SBC is defined according to the presence of thin sclerosis, thick sclerosis, or without sclerosis. When sclerosis is present, it was also classified as partial (when sclerosis was not on the entire contour of the defect) or total (when sclerosis was present on the entire contour of the defect).

Figures 11, 12 and 13 — Examples of margins of SBC.

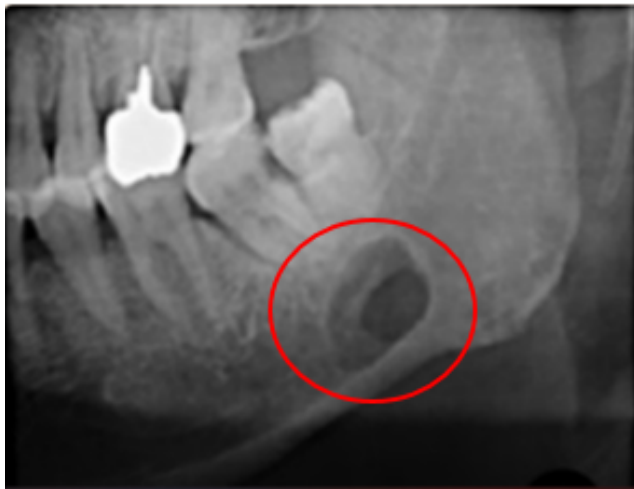

Figure 11: Multilocular SBC with total thin sclerosis

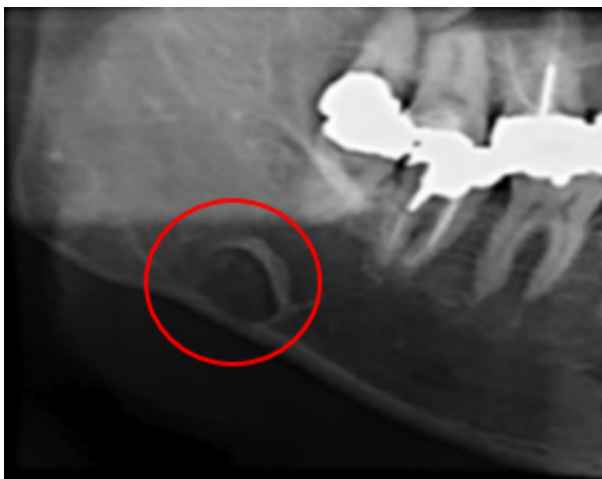

Figure 12: Unilocular SBC with thick sclerosis

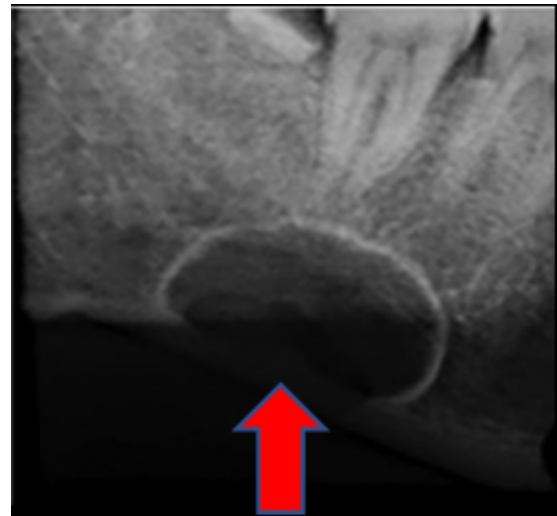

Figure 13: Unilocular SBC without sclerosis

4.2. Internal radiolucency degree

Internal radiolucency was defined as partially radiolucent (when the presence of any bone trabeculae within the defect was detected) or totally radiolucent (when no bone trabeculae were observed within the defect).

4.3. Shape

Oval or Round.

4.4. Locularity

Classified as unilocular or multilocular.

4.5. Topographic relationship between the defect and the mandibular border

Figures 14 and 20: Topographic relationship between the mandibular canal and SBC.

5. Differential Diagnosis

Differential diagnosis for SBC includes traumatic bone cysts, benign salivary gland tumors, intraosseous hemangiomas, central giant cell lesions, simple bone cysts, fibro-osseous lesions, eosinophilic granulomas, metastatic diseases, and ossifying fibromas. For anterior SBC variant or if the defect is above the mandibular canal near to the teeth roots, odontogenic cysts and ameloblastomas may be considered.⁴

6. Management

Since the defect is asymptomatic and not progressive, no treatment is usually necessary.⁹ However, periodic radiographic follow-up is recommended to detect any

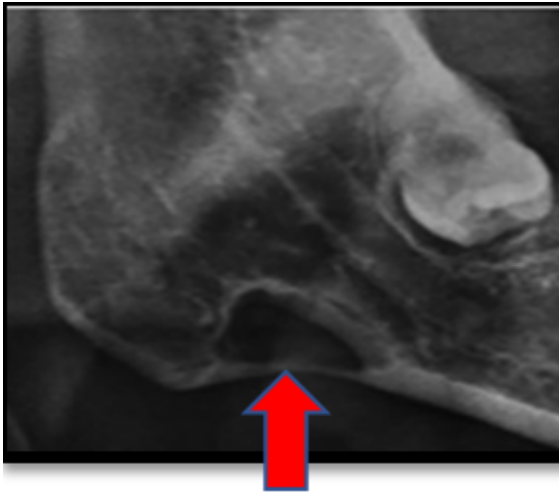


Figure 14: SBC below the mandibular canal

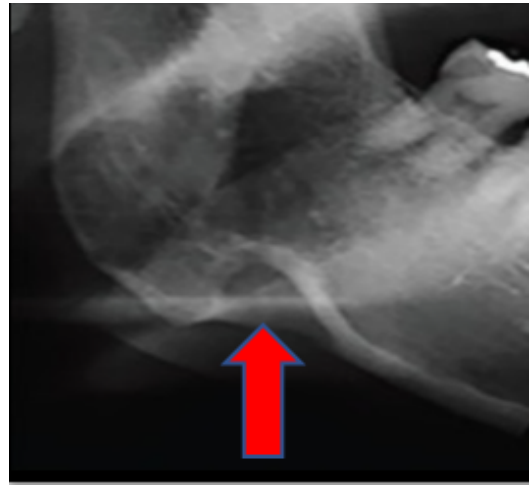


Figure 17: SBC continuous to the mandibular border with clear discontinuity of mandible cortex

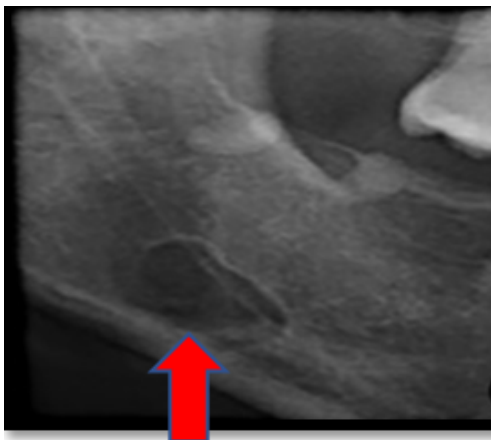


Figure 15: SBC overlapping the inferior wall of mandibular canal and below the upper wall of mandibular canal

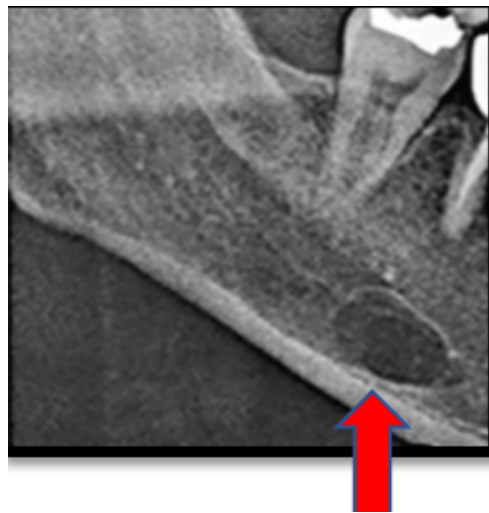

Figure 18: SBC continuous to the mandible base.

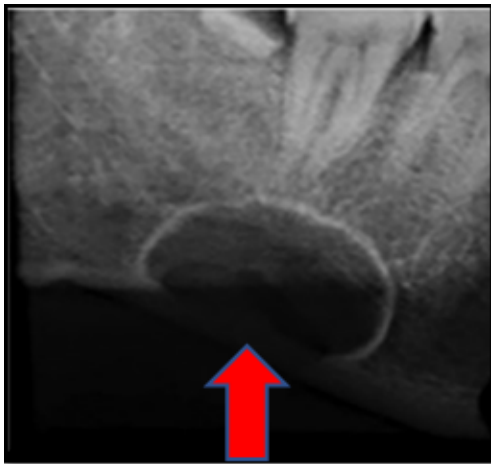

Figure 16: SBC overlapping the upper and inferior walls of the mandibular canal

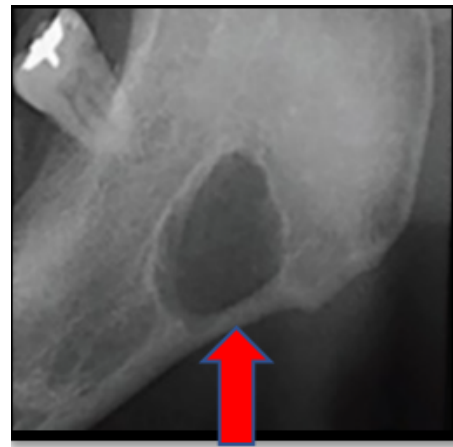

Figure 19: SBC continuous to the mandibular border without discontinuity of mandible cortex

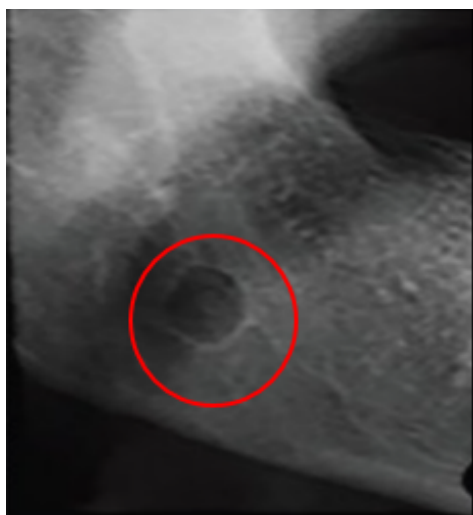

Figure 20: SBC distant from the mandible base

pathological and dimensional changes.¹⁰

7. Conclusion

Stafne bone defects (SBCs) are asymptomatic radiolucent lingual/buccal bone lesions of the lower jaw. Asymptomatic radiolucent lesions in the mandible should be evaluated with advanced non-invasive radiological techniques to achieve a final diagnosis of SBC and to avoid surgical interventions, which are unnecessary options in the management of SBCs, except for symptomatic and/or other concomitant pathologies.

8. Source of Funding

None.

9. Conflict of Interest

None.

References

1. Bayrak NB. A rare presentation of stafne bone cyst. *Oral Maxillofac Surg.* 2020;121(1):80–3.
2. More CB, Das S, Gupta S, Patel P, Saha N. Stafne's bone cavity: a diagnostic challenge. *J Clin Diagnostic Res.* 2015;9(11):16–9.
3. Daniels JS, Albakry I, Samara MI, Braimah RO. Stafne bone cyst: Report of a case and review of the literature. *Saudi J Health Sci.* 2020;9:71–3.
4. Hisatomi M, Munhoz L, Asaumi J, Arita ES. Stafne bone defects radiographic features in panoramic radiographs: Assessment of 91 cases. *Med Oral Patol Oral Cir Bucal.* 2019;24(1):12–9.
5. Dereci Ö, Duran S. Intraorally exposed anterior Stafne bone defect: a case report. *Oral Surg Oral Med Oral Pathol Oral Radio.* 2012;113:1–3.
6. Morita L, Munhoz L, Nagai AY, Hisatomi M, Asaumi J, Arita ES. Imaging features of Stafne bone defects on computed tomography: An assessment of 40 cases. *Imaging Sci Dent.* 2021;51(1):81–6.
7. Shigematsu H, Suzuki S, Osuga T, Okumura Y, Fujita K. 1993.
8. Arijji E, Fujiwara N, Tabata O, Nakayama E, Kanda S, Shiratsuchi Y, et al. 1993.
9. Patil K, Guledgud MV, Chandran P. Stafne bone cyst: a case report with review of literature. *J Anatomical Soc India.* 2017;66(2):4–6.
10. He J, Wang J, Hu Y, Liu W. Diagnosis and management of Stafne bone cavity with emphasis on unusual contents and location. *J Dent Sci.* 2019;14(4):435–9.

Author biography

Komal Deotale, Post Graduate Student

Ashish Lanjekar, HOD

Isha Madne, Post Graduate Student

Charwak Tayade, Post Graduate Student

Zareesh Akhtar, Post Graduate Student

Raksha Jaiswal, Post Graduate Student

Cite this article: Deotale K, Lanjekar A, Madne I, Tayade C, Akhtar Z, Jaiswal R. Stafne bone cyst of mandible: A case report with comprehensive imaging features using cone beam computed tomography and literature review. *Arch Dent Res* 2022;12(2):127-133.