



Case Report

Conservative approach in the management of infected radicular cyst in the anterior maxilla in a pediatric patient: A case report

Zareesh Akhtar^{1*}, Rakhi Chandak¹, Ashish Lanjekar¹, Isha Madne¹, Charwak Tayade¹

¹Dept. of Oral Medicine & Radiology, Swargiya Dadasaheb Kalmegh Smruti Dental College & Hospital, Nagpur, Maharashtra, India



ARTICLE INFO

Article history:

Received 20-12-2022

Accepted 14-01-2023

Available online 20-02-2023

Keywords:

Radicular cyst

Periapical cyst

Periapex cyst

Odontogenic cyst

A periapical cyst

ABSTRACT

Odontogenic cysts are pathological cavities enclosed by fibrous connective tissue and lined with epithelial tissue that develops from odontogenic tissues in the maxilla and mandible's tooth-bearing regions. Trauma or tooth caries is the main cause of radicular cysts or periapical cysts. Pulp necrosis is the outcome of dental caries irritating the pulp cavity. Once the infection has reached the root's tip, it causes periapical periodontitis, which may lead to either a chronic granuloma or an acute abscess. A persistent chronic infection led to the development of a periapical cyst. Radicular cysts are the most prevalent cystic lesions that afflict the jaw. They account for 52% to 68 percent of all cysts affecting the human jaw, making them the most common of all jaw cysts. The paper presents a case report of a 10-year-old pediatric patient who developed a radicular cyst post-trauma and eventually got infected.

This is an Open Access (OA) journal, and articles are distributed under the terms of the [Creative Commons Attribution-NonCommercial 4.0 International](https://creativecommons.org/licenses/by-nc/4.0/), which allows others to remix, and build upon the work non-commercially, as long as appropriate credit is given and the new creations are licensed under the identical terms.

For reprints contact: reprint@ipinnovative.com

1. Introduction

Odontogenic cysts are pathologic cavities lined with epithelial tissue and surrounded by fibrous connective tissue that arises from odontogenic tissues in the tooth-bearing portions of the maxilla and mandible. Bony destruction occurs as a result of cystic diseases in the jaw, which can lead to the resorption or displacement of neighboring teeth.

A frequent jawbone cyst is an odontogenic cyst of the neck and head that can be difficult to diagnose because it has similar clinical and histopathologic characteristics with other odontogenic lesions. In the oral cavity, cystic lesions are common. A cyst is defined as a pathologic cavity with or without fluid or semifluid material. The most common inflammatory odontogenic cystic lesions affecting the jaws are radicular cysts. They are frequently located in the apices of the teeth that are implicated.¹ This case report presents a

case of infected radicular cyst of anterior maxillary region in a pediatric patient.

Dental caries or trauma² are the two main causes of radicular cysts or periapical cysts. The pulp cavity is irritated by dental caries, which causes pulp necrosis. Acute abscesses or chronic granulomas can develop when the infection progresses to the tooth's root's apex, which is known as periapical periodontitis. An ongoing chronic infection caused a periapical cyst to form.³

Radicular cysts are the most prevalent cystic lesions that afflict the jaw. They account for 52%⁴ to 68 percent of all cysts affecting the human jaw, making them the most common of all jaw cysts.⁵ They are typically not symptomatic and are found during routine radiographs. While some exhibit symptoms and need to be found through roentgenogram. Radicular cysts can be treated surgically, such as by enucleation, marsupialization, or decompression, or no surgically using root canal therapy when the cyst is

* Corresponding author.

E-mail address: zareeshakhtar@gmail.com (Z. Akhtar).

tiny.⁶ We are describing a child's instance with a sizable radicular cyst in the front maxilla in this case report.

2. Case Report

A 10 years-old male patient presented to the Department of Oral Medicine and Radiology, with the chief complaint of pain and swelling in the upper front region of the jaw for 2-3 days. The patient recalled a history of trauma in the offending tooth 3 years back. Although the tooth was asymptomatic, it started to develop blackish discoloration. Endodontic treatment was done 20 days back; however, he failed to rehabilitate the tooth. Again, the patient experienced pain and swelling in the same region for 2-3 days, the swelling has gradually increased to present size gradually increasing to the present size. The pain was dull aching and continuous in nature. His past dental history revealed a visit to a private dental clinic where RCO was done and temporary dressing with tooth 21 was given 15 days back. Patient brought with him the previous intraoral periapical radiograph with 21. His past medical history was non-contributory (Figure 1)

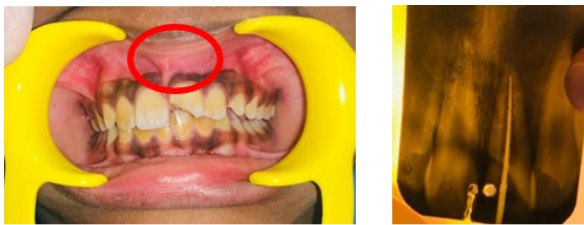

Figure 1: Ellis class II fracture with 21 and previous IOPA of the same

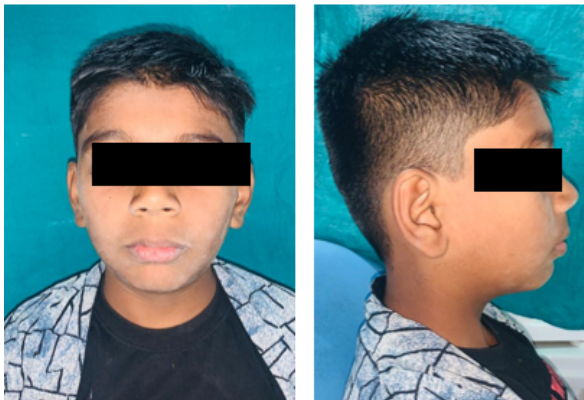

Figure 2: Extraoral profile

A diffuse swelling was discovered during an extraoral examination, extending M-L from the columella of the nose to the left ala of the nose and S-I from the base of the nose to the vermilion border of the upper lip, on the upper front left region of the jaw. The color was the same as

adjacent skin, smooth surface. On palpation the swelling was tender on palpation, soft to firm in consistency, the local temperature was Not raised, crepitus was present, compressibility and fluctuation were negative, and lymph nodes were not palpable (Figure 2).

Intraoral examination revealed localized gingival swelling seen associated with 21,22, Ellis class II fracture 21. Tenderness was +ve with 21 on vertical percussion, Temporary dressing is seen with 21. A provisional diagnosis of Infected radicular cyst w.r.t 21,22 was given. FNAC (Figure 3), pulp vitality, and CBCT (Figure 4) were advised.

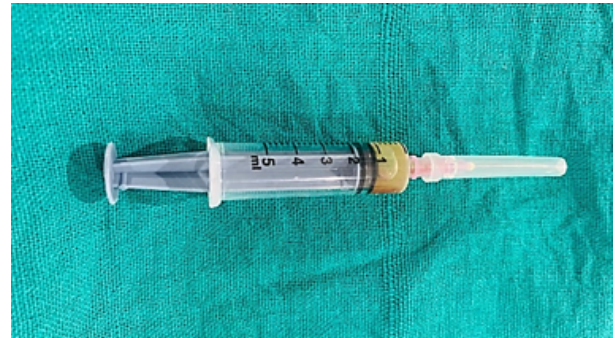

Figure 3: FNAC yielding turbid brown-colored fluid.

FNAC yielded 1 ml of aspirated fluid, which was yellowish-red in color. The wet unstained smear shows RBCs and necrotic debris. The PAP-stained smear prepared from aspirated fluid shows a few RBCs and necrotic debris, and cholesterol crystals. The cytopathologic finding was suggestive of a chronic inflammatory cyst. A pulp vitality test was done using an electric pulp test which revealed 21,22 were non-vital 11,23 were vital.

3. Radiographic Diagnosis

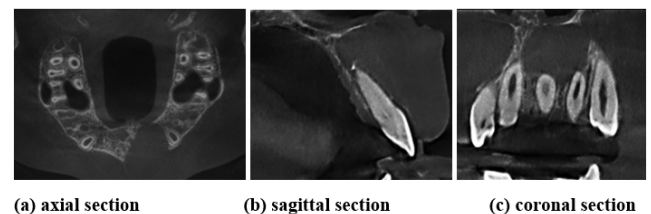


Figure 4: CBCT scan showing A well-defined round unilocular radiolucency seen at the apex of 21,22. Buccal cortical plate expansion was seen.

CBCT was done w.r.t 21,22 which revealed a well-defined round unilocular radiolucency seen at the apex of 21,22 (Non-vital) radiolucency is continuous with the lamina dura of 21,22. Buccal cortical plate expansion is seen which is thinned out. Taking all the clinicopathologic feature into consideration a final diagnosis of Infected Radicular

Cyst with 21,22 was made. Management included surgical enucleation and curettage of the large radicular cyst done along with root canal treatment w.r.t 21, 22.

4. Discussion

Radicular cyst a common jawbone cyst with a challenging diagnosis because of clinical and histopathologic similarity to other odontogenic disorders is the odontogenic cyst of the head and neck, which was first identified by Penumatsa NV et al. in 2013. The oral cavity frequently develops cystic lesions. The inflammatory odontogenic cystic lesions that affect the jaws most frequently are radicular cysts. They are typically found near the apices of the affected teeth.¹ According to J. Lustmann and M. Shear et al., a study of 23 cases revealed that dental caries or trauma are the primary causes of radicular cysts.²

According to E. Mass et al., Dental caries and trauma produce the pulp cavity's inflammation, leading to pulp necrosis. The infection subsequently travels to the apex of the root of the tooth, creating periapical periodontitis, which can result in an acute abscess or a chronic granuloma. A periapical cyst developed as a result of a persistent chronic infection.³

The etiology of radicular cysts was characterized by M. Shear et al. as consisting of three separate phases: initiation, development, and growth.⁴ According to N S Joshi et al., radicular cysts are inflammatory jaw cysts. They begin as epithelial remnants in the periodontal ligament after the death and necrosis of the tooth pulp as a result of apical periodontitis. Radicular cysts are discovered through routine radiography examinations or after an abrupt worsening of the condition.⁶

While radicular cysts are typically asymptomatic and can be detected by radiography, N S Joshi et al. have noted that long-term cases may experience an acute worsening of the cystic lesion, leading to signs and symptoms in the patient such as edema, tooth mobility, and tooth displacement.⁶ According to Cawson RA et al. in 2002 and Natkin E et al. in 1984, nonkeratinized stratified squamous epithelium lines radicular cysts. With a thickness ranging from 1 to 50 cell layers, the lining may be continuous or discontinuous. Early on, the epithelial lining may be proliferative and exhibit a significant, long-lasting inflammatory infiltrate. As the cyst grows larger, its lining becomes quiescent and differentiates to some extent, resembling simple stratified squamous. Most of the inflammatory cell infiltration in the developing epithelium is made up of PMSs.^{7,8}

The children exhibit a variety of pathological abnormalities in the jaw. Considering that odontogenic cysts develop from the odontogenic apparatus epithelium, oral and maxillofacial pathologists are particularly intrigued by them. Radicular cysts are the most frequent of these inflammatory lesions that develop as a result of tooth caries.⁹ Ulopi KS et al. identified stratified

squamous epithelial lining histopathologically, which may point to exocytosis, hyperplasia, or spongiosis. Normal lumen contents include liquid and cellular detritus. An inflammatory infiltrates of mast cells, histiocytes, and lymphocytes mixed with neutrophils, plasma cells, and, in rare cases, eosinophils make up the wall's thick fibrous connective tissue.¹⁰

Radiographically, most radicular cysts present as round or pear-shaped, unilocular, lucent lesions in the periapical area, according to Scholl RJ et al. study from 1999. They are generally smaller than 1 cm in diameter and have a thin cortical bone ring around them. The linked tooth frequently has a big carious lesion or a deep repair. The cyst may cause minor root resorption or displace neighboring teeth. Radicular cysts and periapical granulomas have a radiographic look that is similar, but radicular cysts are less common and often bigger.¹¹

According to Namdar PF et al colleagues in 2012, this cyst presents as a well-defined unilocular radiolucency placed periapical to a tooth with pulp involvement and dental caries, with a size of over 2 cm and a radio-opaque sclerotic border that may be lost in situations of subsequent infection¹² similar finding was found in our case. Jaw cysts can occur in patients of all ages. The onset of maxillary cysts in children is more common in the mixed dentition stage (6–12 years old). The occurrence of internal cystic lesions in the jawbone and compression of the jawbone with an increase in volume leads to displacement of teeth, which affects oral health and may even cause facial appearance changes in patients.¹³

The cyst was symptomatic in the current case, but there was considerable extraoral swelling, which is consistent with Shear M et al. results that radicular cyst is the most common cause of jaw bone enlargement. They are painless until they become infected later. The cyst extends bone hard at first, then springs back and crackles like an eggshell as it expand in size. When the outer cortex is removed, the swelling becomes rubbery and fluctuates.¹⁴

The magnitude of the lesion, its proximity to noble structures, clinical characteristics of the lesion, and the patient's systemic status, according to M. Shear et al., influence treatment possibilities. Nonsurgical RCT may be employed when the lesion is limited to a small area, but surgical treatment such as enucleation, marsupialization, or decompression may be utilized if the lesion is larger.⁴ Practicing a non-surgical approach is the current concept for the management of periapical cysts. However, by the size and extent of the lesion, surgical management was necessary to attain a successful outcome.¹³

5. Conclusion

When the tooth pulp is inflamed, malassez epithelial cells that are resting in the periodontal ligament give rise to an inflammatory cyst called a radicular cyst. The cyst first

develops in the periapical and periodontal regions of a carious tooth. The majority of these lesions affect the entire apex and are radiolucent. The cystic lesion is referred to as a true cyst because it is fluid-filled and surrounded by epithelium. Endodontic therapy, surgical enucleation, and debridement of the cystic lesions were all successful treatments for this case of radicular cysts.

In accordance with the size and location of the cyst, this case study on radicular cysts demonstrates how to successfully identify and treat radicular cysts utilizing both surgery and non-surgical methods. Some authors advocate for the nonsurgical treatment of tiny lesions, even though large lesions are endodontically managed before being surgically enucleated.

6. Source of Funding

None.

7. Conflict of Interest

None.

References

1. Penumatsa NV, Nallanchakrava S, Muppa R, Dandempally A, Panthula P. Conservative approach in the management of radicular cyst in a child: A case report. *Case Rep Dent*. 2013;2013:1–3.
2. Lustmann J, Shear M. Radicular cysts arising from deciduous teeth: Review of the literature and report of 23 cases. *Int J Oral Surg*. 1985;14(2):153–61.
3. Mass E, Kaplan I, Hirshberg A. A clinical and histopathological study of radicular cysts associated with primary molars. *J Oral Pathol Med*. 1995;24(10):458–61.
4. Shear M. Cysts of the Oral Regions. 4th ed. Wright, Bristol, UK; 1992. p. 136–70.
5. Killey HC, Kay LW. Benign Cystic Lesions of the Jaws, Their Diagnosis and Treatment. 2nd ed. Harcourt Brace/Churchill Livingstone; 1977. p. 164.
6. Joshi NS, Sujan SG, Rachappa MM. An unusual case report of bilateral mandibular radicular cysts. *Contemp Clin Dent*. 2011;2(1):59–62.
7. Cawson RA, Odell EW, Porter S. Cawson's essentials of oral pathology and oral Medicine. 7th ed. and others, editor; 2002. p. 102–23.
8. Natkin E, Oswald RJ, Carnes LI. The relationship of lesion size to diagnosis, incidence, and treatment of periapical cysts and granulomas. *Oral Surgery, Oral Medicine. Oral Pathol*. 1984;57(1):82–94.
9. Kesharwani P, Hussain SA, Sharma N, Karpathak S, Bhanot R, Kothari S. Massive radicular cyst involving multiple teeth in the pediatric mandible-A case report. *J Fam Med Prim Care*. 2020;9(2):1253–6.
10. Uloopi KS, Shivaji RU, Vinay C, Shrutha SP, Chandrasekhar R. Conservative management of large radicular cysts associated with non-vital primary teeth: A case series and literature review. *J Indian Soc Pedod Prev Dent*. 2015;33(1):53–6.
11. Scholl RJ, Kellett HM, Neumann DP, Lurie AG. Cysts and cystic lesions of the mandible: clinical and radiologic-histopathologic review. *Radiographics*. 1999;19(5):1107–31.
12. Pekiner FN, Borahan O, Ugurlu F, Horasan S, Sener BC, Olgac V. Clinical and radiological features of a large radicular cyst involving the entire maxillary sinus. *Clin Exp Health Sci*. 2012;2(1):31–6.
13. Zhang J, Zhao T, Piao Z, Ouyang K. Evaluation of marsupialization for radicular cysts in children. *Res Square*. 2022;p. 1–12. doi:10.21203/rs.3.rs-1496321/v1.
14. Shear M, Speight P. Cysts of the Oral and Maxillofacial Regions. Singapore: Blackwell: Wiley; 2007. p. 240.

Author biography

Zareesh Akhtar, Post Graduate Student

Rakhi Chandak, Reader

Ashish Lanjekar, Professor & HOD

Isha Madne, Post Graduate Student

Charwak Tayade, Post Gradated Student

Cite this article: Akhtar Z, Chandak R, Lanjekar A, Madne I, Tayade C. Conservative approach in the management of infected radicular cyst in the anterior maxilla in a pediatric patient: A case report. *Arch Dent Res* 2022;12(2):123-126.