



Case Report

Implant exfoliation within 10 days: A case report

Rashmi Bele¹, Priyanka Ghogare^{2*}, Sneha Puri², Mahvash Fatema², Vivek Patil²

¹Private Practitioner, Amravati, Maharashtra, India

²Dept. of Periodontology, Swargiya Dadasaheb Kalmegh Smrutii Dental College and Hospital, Nagpur, Maharashtra, India



ARTICLE INFO

Article history:

Received 15-12-2022

Accepted 10-01-2023

Available online 20-02-2023

Keywords:

Implant
Osseo integration
Bone graft
Bone defect

ABSTRACT

Implant failure can be because of many reasons, it is difficult to determine the exact cause of the implant failure, especially when there are many factors contributing.

This case report reviews the case in which implant failure occurred. A female patient of 34 years came with the complaint of edentulous space in the region of 11. An implant was placed which got exfoliated on 10th day.

In this case Norris Implant 3.75 /8 was placed in the region of 11. 6 months back extraction was done with respect to 11 but after 6 months the bone formation was not adequate. The same region was having buccal cortical plate defect. An implant planning was done.

During implant placement we came to know that buccal cortical plate defect was large, as there was insufficient bone so threads of implant were exposed so Osseo graft (periocol) and collagen membrane was placed for additional bone support.

This case highlights the unusual implant failure that occurred because of the inappropriate analyzing of the bone defect and inaccurate planning of the implant.

This is an Open Access (OA) journal, and articles are distributed under the terms of the [Creative Commons Attribution-NonCommercial 4.0 International](https://creativecommons.org/licenses/by-nc/4.0/), which allows others to remix, and build upon the work non-commercially, as long as appropriate credit is given and the new creations are licensed under the identical terms.

For reprints contact: reprint@ipinnovative.com

1. Introduction

In the past few years, dental implants have extended the use of prosthetic appliances for edentulous and partially edentulous patients for their discomfort regarding absence of teeth. Dental implants are medical devices, surgically implanted into the jaw to restore a person's ability to function or for their aesthetic concern.¹

The main goal of implant therapy is to provide long term replacement for missing dentition on ideally positioned Osseo integrated dental implants whose lifespan will be long enough to serve patient.

Numerous studies have reported high implant survival rates if placed with ideal and proper planning, although increasing complications, including implant loss, have also

been described. Dental implant placement is a widely used treatment that provides functional and esthetic resolution for patients suffering from tooth loss.

Unsuccessful implant surgery can be easily identified and pointed out by the mobility of the implant, continuous radiolucency around the implant, peri-implantitis with suppuration, or subjective complaints from the patient.²

Till date no specific criteria for unsuccessful dental implants have been defined or specified. The inability of tissue to establish and or maintain osseointegration with the implant in patients is thought to cause implant failures even if patient follows all the instructions given by the doctor.

Implant failures have been frequently associated with factors such as compromised bone quality, insufficient bone volume causing reduced blood supply, inadequate primary implant stability, and overload of masticatory forces.³

* Corresponding author.

E-mail address: priyankaghogare12@gmail.com (P. Ghogare).

Implant failures can be further divided as early failures or late failures, depending on when they occur, that is, before abutment connection (early) or after implant loading (late). This subdivision is necessary because the etiology of these two kinds of failures is often different.⁴

Implants early failure results from an inability to establish an intimate bone-to-implant contact and improper placement of the implant with the inappropriate planning. This means that bone healing after implant insertion is impaired or jeopardized causing failure of the implant.

In some cases its also found that early implant failures were because of the contributing factors such as: implants dimensions and type such as (width, length, surface, thread design, shape, etc), the quality and quantity of the bone site, surgery-related factors (flap/flapless, submerged/ non submerged positioning, insertion torque [related to bone density], bone standard drilling protocol/adapted drilling in low-density bone, Piezosurgery/conventional drilling, etc), use of grafted bone, and systemic factors such as genetic predisposition, smoking, and metabolic disorders.^{5,6}

In this case report we are going to discuss the case in which the implant failed in just 10 days after its placement.

2. Materials and Methods

The typical methodology employed in the investigation and analysis of implant failures that occur, consists of a sequence of successive stages of implant placement, subjected to variations, depending upon the nature and the size of the failed component/assembly that is implant and the requirements of each particular study, with the ultimate goal to identify a plausible failure scenario.

Collection of background data and selection of sample. Identification, preservation, and cleaning of all failed parts. Determination of failure mechanisms. Analysis of all the evidence and formulation of conclusions.

3. Clinical Report

A female patient of age 34 year from Nagpur, central part of India, reported to the department of Periodontology, Swargiya Dadasaheb Kalmegh Smruti Dental College and Hospital. With partially edentulous maxilla with the complaint of missing tooth in the anterior region of the maxilla. No past history of diabetes or hypertension. No history of drug use and drug allergy.

Patient got her tooth extracted 6 months back with generalized aggressive periodontitis as it was grade III mobile. Buccal cortical plate defect was present in the same region and healing was not effective.

After the evaluation of clinical and radiographic data, the treatment planning resulted in the insertion of one implant in anterior region of the maxilla.

Implant placed was Norris implant of dimension 3.75mm diameter and length 8mm.

The prosthodontic restoration consisted of crown placement from the department of Prosthodontics. Later like this way the implant planning was completed.

It was decided that implant placement could be attempted at the time. For the fabrication of a surgical template an alginate impression was taken.

After infiltrating appropriate anesthetic in the area crestal and crevicular incision given with a Bard Parker blade 15 flap was reflected by using periosteal elevator to expose the ridge.

Bone width was measured and after following the manufacturers protocol for implant placement bone was drilled with the help of the surgical template.

After final drill, parallel pin was placed. After examining the position of parallel pin, Norris implant of dimension 3.75 / 8 was placed in the apicocoronally depth of bone 12 mm. Periapical radiographs were taken prior to implant placement; they did reveal pathology but not of much depth. During implant placement we came to know that buccal cortical plate defect.

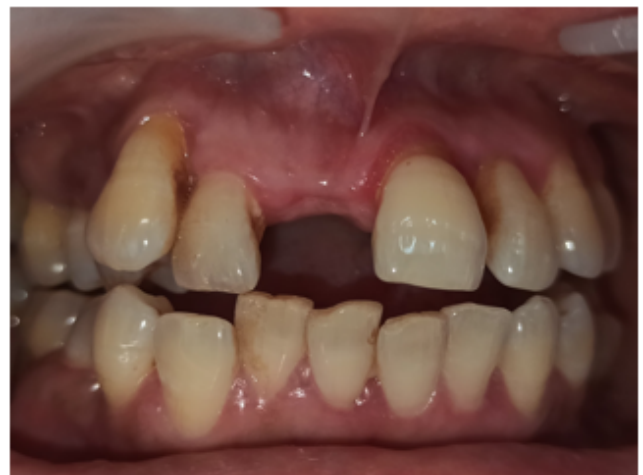

Figure 1: Pre-operative

4. Placement of the Bone Graft

Primary stability was achieved for the implant. As buccal cortical plate was thin, to avoid failure of implant because of the insufficient bone.

Hence, in the defect, particulate bone graft material and a bioabsorbable collagen membrane was placed over the graft. Tension free primary wound closure is achieved. Wound adaptation was accomplished with single interrupted sutures. Post surgically the patient was prescribed Chlorhexidine 0.12% mouth rinse 30ml BID for seven days and for pain Ibuprofen 200mg was suggested.

After 10 days patient arrived with exfoliated implant.

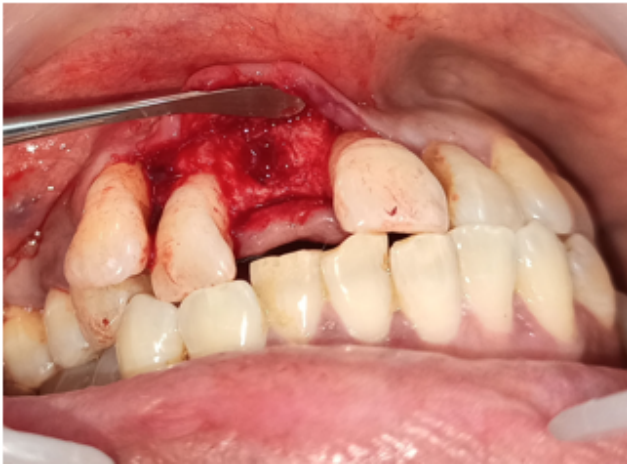

Figure 2: Drilling done

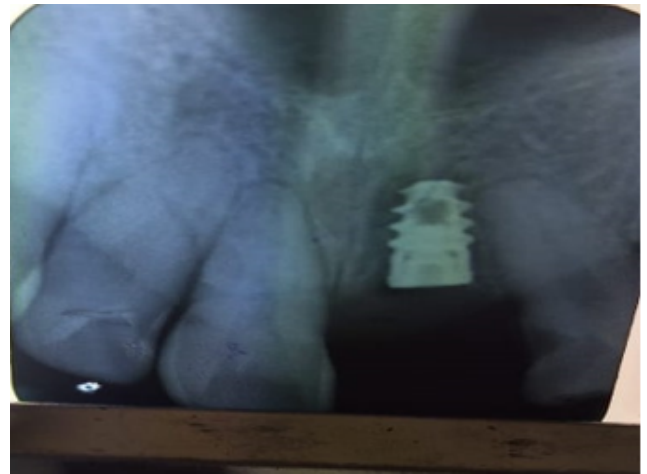


Figure 5: Implant placed

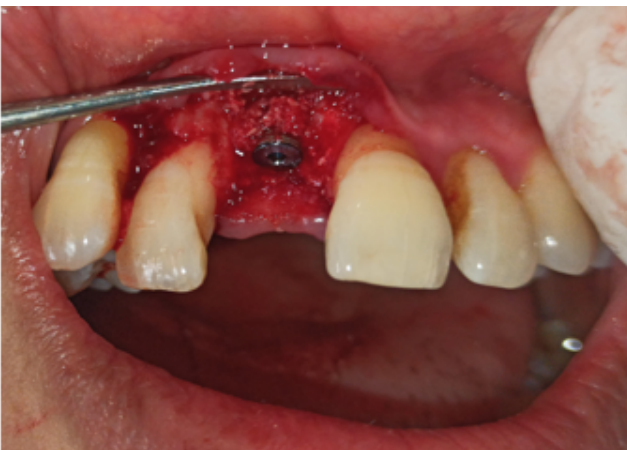

Figure 3: Bone graft placement.



Figure 6: Exfoliated implant

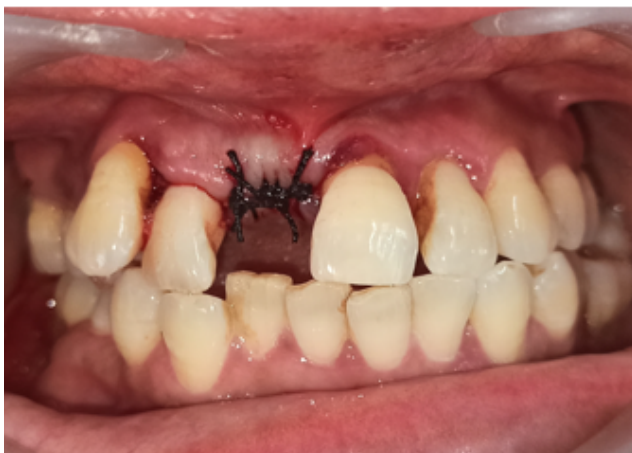

Figure 4: Sutures placed

5. Discussion

Early exfoliation of the implant is the case. An implant was placed in proper aseptic condition, and patient also followed all the instructions given.

Factors causing early failures of implants can be patient related factors (smoking and jaw bone), and the other was implant-related (length and width). However, we are aware that there are further local and systemic risk factors also which can cause the implant failure.

In this case the implant failure is because of the bone defect in the implant region.

Regarding implant length, our results are in agreement with many studies reporting that a short length is associated with implant failure. Misch et al.⁷ observed a low success rate (85.3%) for implants less than 10 mm in length. Olate et al.⁸ concluded that there was a significant relationship between early implant failure and short implant length (6–9 mm).

It is noteworthy that since narrow and short implants are placed in areas where there is limited space or insufficient volume of bone, either buccolingually or axially, both factors will affect on clinical performance, because the total surface in contact with the bone tissue is restricted.

In fact, because of bones low biomechanical properties, this kind of bone often fails to provide adequate primary stability for implants, which is indispensable for the formation of efficient bone-to-implant contact.

Olmedo-Gaya et al. reported that the risk of early implant failure is higher in men, participants with severe periodontal disease or short implants in his retrospective studies.⁹ A recent study described the early loss of implants with short and narrow implants. They also found that the loss of implants was more common with narrow implants (<3.5 mm); shorter implants were also more likely to be lost, but not significantly in Z. Baqain et al.⁵ study.

Concerning the bone quantity and quality of the implant site, as the contributing factor for implant that failed up as stated by the B. R. Chrcanovic et al.¹⁰

6. Conclusion

Accurate implant placement is the great challenge to the dentists. Use of recent advances help us to plan implant accurately. Successful implant placement and later abutment and crown placement if gone correct then it functions almost similar like natural tooth.

7. Source of Funding

None.

8. Conflict of Interest

None.

9. Acknowledgment

We thank all the authors for their great support and contribution in this case report.

References

1. Swierkot K, Lottholz P, Flores-De-Jacoby L, Mengel R. Mucositis, peri-implantitis, implant success, and survival of implants in patients with treated generalized aggressive periodontitis: 3-to 16-year results of a prospective long-term cohort study. *J Periodontol*. 2012;83(10):1213–38.
2. Albrektsson T, Lekholm U. Osseointegration: Current state of the art. *Dent Clin North Am*. 1989;33(4):537–54.
3. Kronström M, Svenson B, Hellman M. Early implant failures in patients treated with Brånemark System titanium dental implants: A retrospective study. *Int J Oral Maxillofac Implants*. 2001;16(2):201–7.
4. Van Steenberghe D, Jacobs R, Desnyder M. The relative impact of local and endogenous patient-related factors on implant failure up to the abutment stage. *Clin Oral Implants Res*. 2002;13(6):617–22.
5. Baqain ZH, Moqbel WY, Sawair FA. Early dental implant failure: Risk factors. *Br J Oral Maxillofac Surg*. 2012;50(3):239–43.
6. Klokkevold PR, Han TJ. How do smoking, diabetes, and periodontitis affect outcomes of implant treatment? *Int J Oral Maxillofac Implants*. 2007;22(1):173–202.
7. Misch CE, Steingra J, Barboza E. Short dental implants in posterior partial edentulism: A multicenter retrospective 6-year case series study. *J Periodontol*. 2006;77(8):1340–7.
8. Olate S, Lyrio M, De Moraes M. Influence of diameter and length of implant on early dental implant failure. *J Oral Maxillofac Surg*. 2010;68(2):414–9.
9. Gaya MO, Moreno FJM, Cavero EC, Capilla MV, Castillo JD. Risk factors associated with early implant failure: A 5-year retrospective clinical study. *J Prosthet Dent*. 2016;115(2):150–5.
10. Chrcanovic BR, Kisch J, Albrektsson T, Wennerberg A. Factors influencing early dental implant failures. *J Dent Res*. 2016;95(9):995–1002.

Author biography

Rashmi Bele, Private Practitioner

Priyanka Ghogare, Post Graduate Student

Sneha Puri, Reader

Mahvash Fatema, Post Graduate Student

Vivek Patil, Post Graduate

Cite this article: Bele R, Ghogare P, Puri S, Fatema M, Patil V. Implant exfoliation within 10 days: A case report. *Arch Dent Res* 2022;12(2):119-122.