



Review Article

Role of hyaluronic acid during periodontal therapy & post-periodontal surgeries

Kirti Shukla^{1*}, Kranti Kiran Pebbili¹¹Dept. of Medical Affairs, Dr. Reddy's Laboratories, Hyderabad, Andhra Pradesh, India

ARTICLE INFO

Article history:

Received 11-01-2023

Accepted 21-01-2023

Available online 20-02-2023

Keywords:

Hyaluronic acid

Periodontitis

Post-periodontal surgery

Wound healing

ABSTRACT

Hyaluronic acid (HA) is a glycosaminoglycan with a high molecular weight found abundantly in the extracellular matrix of soft periodontal tissues. HA has anti-bacterial & anti-inflammatory action in periodontitis & gingivitis. It is plausible that HA administration to diseased periodontal sites is beneficial during periodontal healing as well as post-surgical healing, thus aiding in the management of the periodontal disease. Data gathered from clinical evidence exhibits that HA's tissue repairing and wound healing could be beneficial not only in patients affected by gingivitis and periodontitis but also during as well as post-periodontal surgery, with significant improvement in their quality of life. This review discusses the physicochemical, biochemical, and pharmacotherapeutic uses of HA during periodontal therapy as well as post-periodontal surgery.

This is an Open Access (OA) journal, and articles are distributed under the terms of the [Creative Commons Attribution-NonCommercial 4.0 International](https://creativecommons.org/licenses/by-nc/4.0/), which allows others to remix, and build upon the work non-commercially, as long as appropriate credit is given and the new creations are licensed under the identical terms.

For reprints contact: reprint@ipinnovative.com

1. Introduction to Hyaluronic Acid

Hyaluronic acid (HA) is a linear polysaccharide occurring naturally in the synovial fluid, the extracellular matrix of connective tissue, and other tissues. It has several structural & physiological functions, such as tissue lubrication, regulation of osmotic pressure, growth factors interactions, and cellular/extracellular interactions. These function helps to maintain the tissue's homeostatic & structural integrity.¹ Evidences on the physicochemical properties and physiological role have shown it as an ideal for medical, pharmaceutical, and cosmetic purposes.²

HA plays a vital role in migration, cell adhesion, and differentiation mediated by numerous binding proteins and cell-surface receptor CD44.^{3,4} Additionally, the negative charge and substantial size of HA allow it to take in lots of water and exert pressure on the nearby tissue, producing an expansion of the extracellular space. Henceforth, HA uses a buffering action to the masticatory forces on the periodontal

ligament. Additionally, it holds anti-inflammatory and bacteriostatic effects.⁵ It also has a major role in almost all the phases of wound treatment.⁶

HA enables cell migration and isolation throughout tissue regeneration. Application of exogenic HA is beneficial in experimental animals for wound healing.^{7,8}

In dentistry, the preliminary clinical trials on HA were conducted way back in 1997. A study by Vangelisti, Pagnacco et al. (1997) revealed that hyaluronate possesses anti-inflammatory, bacteriostatic and anti-edematous effects which can have a potential role in the treatment of gingivitis as well as periodontitis. Exogenic HA shows anti-inflammatory effects by exhausting metalloproteinases, prostaglandins, and other bioactive molecules.⁹ Anti-edematous effects were associated with osmotic activity. The high concentration of LMW HA has the most bacteriostatic effect as it stimulates the phagocytic activity of macrophages. It was used as an adjunct to mechanical therapy due to HA's tissue healing properties.¹⁰ Nevertheless, it is plausible that HA could be effective in periodontal tissue regeneration as well as in periodontal

* Corresponding author.

E-mail address: Kirtishukla@drreddys.com (K. Shukla).

disease treatment.^{11,12} This review helps to more thoroughly understand the biochemical and pharmacological role of HA in post periodontal surgery.

2. History & Chemistry of HA

2.1. History

French scientist Portes noted that mucin from the vitreous body of eye was not the same as other mucoids in cornea and cartilage and termed it "hyalomucine" way back in 1880. However, it was only in 1934 that Meyer and Palmer isolated a polysaccharide consisting of an amino sugar and a uronic acid from bovine vitreous humor and called it Hyaluronic acid, derived from "hyaloid" and "uronic acid."¹³ In 20th century, a gradual awareness about biological functions established HA's advancement as a medicine for several therapies. The extraction of HA from animal tissues were increasingly enhanced, nonetheless had issues of contamination from microorganisms or proteins. To date, bacterial fermentation is one of the favorable methods for production of HMW Hyaluronic acid. Although, there are different sources to extract Hyaluronic acid, the variety of bacteria produces HA and stimulates bacterial fermentation. The most important pre-purification steps include centrifugation and numerous precipitations along with polar solvents, though ultrafiltration & size exclusion chromatography are the most chosen method for purification.¹⁴

2.2. Chemistry

The HA is a linear chain consisting of recurring disaccharide connected with β 1,4-glycosidic bond. Disaccharide individually contains d-glucuronic acid and N-acetyl-d-glucosamine connected by β -1,4-glycosidic bond.¹⁵ HA is negatively charged because of carboxylate groups. Thus, it forms hydrophilic salts with distinctive capacity of binding and retaining H₂O, which allows tremendous viscoelasticity, biocompatibility, hygroscopic properties great and water retention capacity. Thus, it plays a role as a lubricant, water balance retention-flow-resistant regulator, space filler, and shock absorber.¹⁴

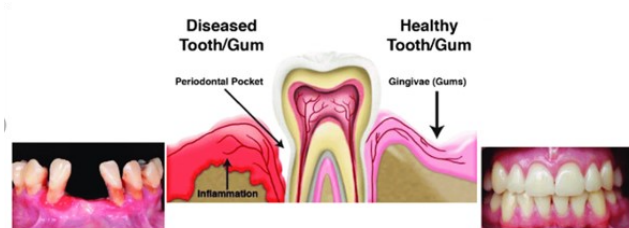

Figure 1: Characteristics of periodontitis

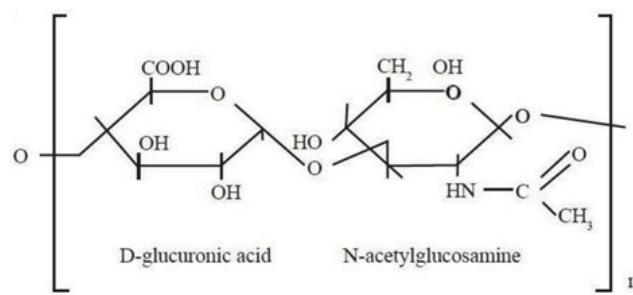


Figure 2: Chemical structure of hyaluronan

3. Physical & Biological Properties of HA

HA is widely found in humans as well as in animals, which include rabbits, roosters, bovines, and bacteria. The total content of HA in human is about 15 g for a 70-kg adult. Cells are surround by HA and in the extracellular matrix (ECM) of connective tissues.^{16,17}

3.1. Hyaluronic acid has the following properties

1. **Hygroscopic nature:** HA is highly hygroscopic in nature. After Hyaluronic acid contained into an aq. solution, Hydrogen appears among the adjacent; acetyl and carboxyl groups, which maintains conformational stiffness and retain water. It functions as physical background material in space-filling, shock absorption and lubrication.
2. **Bacteriostatic effect:** Evidence on regenerative operative procedures indicates that reducing bacterial burden at the wound area improves regenerative treatment. Elevated concentration of moderate to lower MW Hyaluronic acid has the most significant bacteriostatic effect, more specifically on *Prevotella oris*, *Aggregatibacter actinomycetemcomitans*, & *Staphylococcus aureus* strains, which are mainly observed in periodontal as well as in gingival wounds. Use of hyaluronic acid during surgeries reduces the contamination around the wound, thus reducing the possibility of post-operative infection and fostering inevitable regeneration.¹⁸
3. **Viscoelastic properties:** HA helps in periodontal regenerative processes by sustaining spaces and surfaces. The viscoelastic properties slow down the infiltration of viruses and bacteria in treating periodontal diseases.¹⁸
4. **Anti-oedematous:** HA exhibits a non-ideal osmotic pressure, which improves exponentially instead of linearly with rising concentration of hyaluronan. This property provides HA osmotic buffering capacity, which possibly regulates the water content in a tissue.¹⁰
5. **Antioxidant:** HA behave as an antioxidant by scavenging ROS and controls inflammatory responses.

Therefore, it might help to steady the granulation tissue matrix.¹⁹

6. **Biocompatibility & non-antigenicity:** The high biocompatible and non-immunogenic environment of HA results in various proven functions, such as fluid in arthritis⁹; and also in facilitating the regeneration/healing of bone, periodontal tissue and surgical wounds.¹⁰
7. **Anti-inflammatory:** Anti-inflammatory effect of HA is because of its exogenous role by draining metalloproteinases, prostaglandins, and other bio-active molecules.

3.2. Role of HA in healing of periodontal tissues

Healing of periodontal tissue involves phases of extremely reproducible and firmly regulated biologic events that gather and debride the wounded tissue, foreign substance, and microbial cells [Figures 1 and 2]. Phases ends with the growth and maturation of ECM which restores tissue endurance.^{20,21}

1. **Inflammatory phase:** In the early stages of inflammation, HA plays a number of tasks. For example, it interacts with the fibrin clot to provide structural support, which controls the infiltration and ECM into the inflammatory area. According to Hakansson et al. HA in adherence and migration of macrophages and polymorphonuclear leukocytes at the inflamed region, phagocytosis & destroying invasive microbes. Such events would agree to lessen the colonization and proliferation of anaerobic pathogen in gingival crevice & nearby periodontal tissues.²² HA also inhibit periodontal pathogen colonization by directly preventing microbial proliferation. HA produces proinflammatory cytokines by fibroblasts, osteoblasts, cementoblasts and keratinocytes which boost the inflammatory response & subsequently promote HA production by endothelial cells. It indirectly acts to lessen the inflammation & alleviate the granulation tissue through blocking degradation of the ECM proteins by serine proteinases obtained from inflammatory cells as healing continues.^{23,24}
2. **Granulation phase & re-epithelization:** HA stimulates proliferation of cell, converts matrix cells into granulation tissue matrix. Hyaluronic acid in mineralized tissues progressively switched by a temporary mineralized callus.^{25,26} During late granulation phase, existing HA is depolymerized by hyaluronidases instigating the development of LMW HA & an modification in the composition of the granulation tissue. LMW HA fragments produce after hyaluronidase action stimulate the production of angiogenesis inside wound area.²⁷

3. **Bone regeneration:** HA increase bone regeneration due to proliferation, chemotaxis and variation of mesenchymal cells. Hayaluronic acid shares bone induction qualities with osteopontin and bone morpho genetic protein 2.^{28,29}

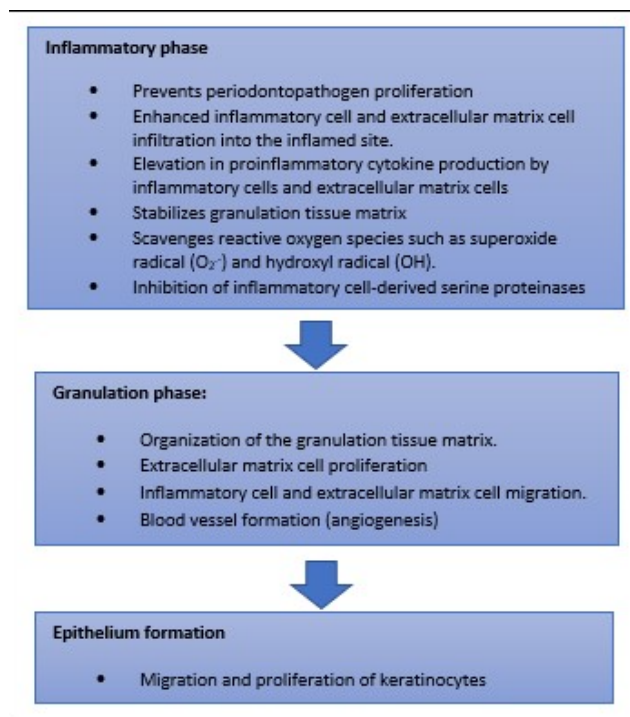


Figure 3: Phases of periodontal healing

3.3. Studies of HA in periodontal tissue healing and regeneration

Studies based on the use of HA in post periodontal surgery, gingivitis, periodontitis were included. Clinical studies were searched in Google Scholar and PubMed using keywords ("hyaluronic acid" and "post-periodontal surgery"), ("hyaluronic acid" and "periodontitis"), ("hyaluronic acid" and "gingivitis").

3.4. HA in gingivitis

HA has emerged as a beneficial adjuvant in the management of gingivitis. Jentsch et al. 2003 revealed that 0.2% HA twice daily for three weeks is effective in patients affected by gingivitis, improve PI, PBI, and GCF.³⁰ Pistorius et al. 2005 also showed that HA reduces SBI, PBI values, and GCF.³¹ Likewise, Sahayata et al. 2014 revealed that 0.2% HA gel in inflamed gingiva for four weeks adjunctly with oral hygiene & scaling resulted in significant improvement in the GI and PBI.³²

Table 1: Overview of clinical trials

Type of study	Interventions	N	Duration	Results	Ref
Gingivitis					
RCT	25 patients with 0.2% HA gel or placebo	50 male patients	21 days	HA group had great improvement for the PI and papilla bleeding index beginning with day 7. CF variables had significant improvement in the center of the inflammation area	30
RCT	40 patients used a spray containing HA and 20 patients used placebo 5 times daily for 1 week.	60 patients with clinical signs of gingivitis	1 week	Decrease in the SBI in the HA group was observed at T2 and at T3. The PBI values and the GCF decreased in the HA group	31
RCT	Negative control group: scaling, placebo control group: scaling + placebo gel test group: scaling+ 0.2 % HA twice daily for a 4 week	105 chronic plaque induce gingivitis	4 weeks	Significant variation in GI and PBI in HA group	32
Chronic periodontitis					
RCT	HA gel or placebo twice a day for 1 month	21	30 days	HA reduced proliferation index of the gingival epithelium and fibroblastic cells	33
RCT	HA gel administered subgingival	12 patients with chronic periodontitis	12 weeks	Lower bleeding on probing scores in the HA group at 12 weeks (P <0.05). Mean probing depth reductions at 12 weeks (1.0 +/- 0.3 mm.)	34
RCT	0.2 mL of 0.8% HA with SRP and after one week	18 patients moderate to severe chronic periodontitis	2 weeks	Reduction in BOP, API, PPD, CFUs and CAL in the test sites than control group.	35
RCT	1 mL of 0.2% HA gel or placebo at baseline and at the end of weeks 1, 2, and 3.	26 patients with chronic periodontitis	12 weeks	The test sites showed statistically significant improvement in GI and BI at 6 and 2 weeks than control sites	36
RCT	0.2% HA gel or placebo after SRP and 1 week post treatment	33 patients with chronic periodontitis	12 weeks	In the HA group, this combined treatment showed a significant improvement in all clinical parameters: BOP, PPD, and CAL, at 12 weeks post therapy in comparison to the control group treated with SRP only	37
RCT	Patients received 0.5 mL of amino acids and HA gel or 0.5 mL of placebo gel	11 patients with moderate-severe chronic periodontitis	90 days	HA showed significant reduction in probing depth and bleeding on probing than control group.	38

Continued on next page

Table 1 continued

RCT	16 mg/mL of cross-linked and 2 mg/mL of non-cross-linked HA or placebo	100	3 months	HA in periodontal therapy decreased in inflammation, measured by bleeding on probing by 6% compared to the control group and gain in periodontal attachment, 1 mm more than control group.	39
Post-Periodontal Surgery Comparative Study	N=19 defects	Esterified HA (fibers packed in periodontal defects)	One year post study	PPD reduced, gingival recession increased, and CAL gain.	40
RCT	Sites treated with hyaluronic acid) and treated with open flap debridement (control group).	40 patients with a two-wall infrabony defect	During the surgery	The treatment of infrabony defects with HA showed additional benefit in gCAL , probing depth reduction, and predictability compared to open flap debridement	41
RCT pilot study	Esterified form of HA gel	19 adult patients with mild chronic periodontitis and shallow pockets	3 weeks	BOP in the HA group reduce 92.7% and GI of 96.5%. The difference of PPD in both areas was statistically significant (p<0.01) in favour of the HA gel treated zone.	42
RCT	16 mg/mL cross-linked HA and 2 mg/mL non-cross-linked HA.5 mL of 0.8% HA gel or placebo	100 patients with moderate periodontitis	3 months	There was a significant reduction in inflammation, measured by bleeding on probing (-6% compared to the control group) and gain in periodontal attachment (1 mm more than control group)	43
Clinical trial	Esterified low-molecular HA preparation (EHA)	9 patients with periodontal defects	Follow up study (10 days, 6, 9 & 24 months)	Clinical results showed gCAL gain of 2.6 mm at the treated area.	44

3.5. HA in chronic periodontitis

The HA gel decreases cell proliferation in epithelial cells including lymphocytes, fibroblasts and subsides the inflammatory response and periodontal lesion in chronic periodontitis.³³ Johannsen et al.2009 noted that twice subgingival administrations of 0.8% Hyaluronic acid gel reduce bleeding in the treatment group.³⁴ Comparably, Polepalle et al.,2015 demonstrated that application of 0.8% Hyaluronic acid gel for seven days, reduced the BOP, plaque index, PPD, CAL, and CFU.³⁵ Gontiya et al., 2012 noted that application of 0.2 % Hyaluronic acid gel with Scaling & root planning (SRP) in chronic periodontitis patients improved the GI and BI and decreased in inflammatory infiltrate.³⁶

Rajan et al. 2014 showed that Hyaluronic acid application directly after Scaling & root planning and seven days post therapy is effective in chronic periodontitis. Combined treatment demonstrated a considerable progress in all clinical parameters: BOP, PPD, and CAL, at 12 weeks post-therapy compared with SRP alone.³⁷

Bevilacqua et al.2012 showed that 0.5 mL of amino acids and HA gel subsequent to ultrasonic mechanical instrumentation reduced PPD and BOP in moderate to severe chronic periodontitis in comparison to ultrasonic debridement alone.³⁸

3.6. HA in post-periodontal surgery

El-Sayed et al. 2012 evaluated the clinical impact of hyaluronan gel (0.8%) in combination with periodontal surgery. Substantial improvement ($P < 0.05$) was observed in the treatment and the control site after 3 & 6 months. The treatment site displayed greater improvement in clinical attachment level (CAL) & reduction in gingival recession (GR).³⁹ Leonardo et al. 2009 examined the clinical efficiency of esterified HA for periodontal imperfections. During the study, nineteen defects (one mandibular molar and eighteen infrabony furcation) were treated using hyaluronic acid fibers. One year treatment displayed 5.8 mm reduction in the mean probing pocket depth (PPD) and 3.8 mm benefit in the attachment.⁴⁰ Briguglio et al.2013 investigated the use of HA for the treatment of infrabony periodontal defects. The mean CAL gain of 1.9 ± 1.8 mm, was obtained with PD reduction of 1.6 ± 1.2 mm.⁴¹ Pilloni et al. 2012, assessed the benefit of hyaluronic acid gel on periodontal considerations. Study results that HA gel has an effect in alleviating the inflammation of gingival and increase the periodontal CI.⁴² Olszewska-Czyz et al. 2021 suggested that HA has greater gain in clinical attachment and reduced bleeding on probing, which indicates reduced inflammation and periodontal regeneration.⁴³ According to Ballini et al. 2009, HA has good abilities for regeneration of bone in infrabony defects.⁴⁴

Abbreviations: papillary bleeding index -PBI, and gingival crevicular fluid-GCF, sulcus bleeding index -SBI gingival index -GI, bleeding on probing- BOP, plaque index — PI, bleeding on probing pocket depth -PPD, clinical attachment level-CAL, and colony-forming units-CFUs, bleeding index-BI, probing pocket depth-PPD

To summarize, Hyaluronic Acid is broadly used in several branches of medicine with potential use in dentistry to treat inflammatory diseases. In the periodontium, hyaluronic acid is present in smaller amount in mineralized tissues while abundant in non-mineralized tissues.

While SRP is the first step in the management of periodontal diseases, use of adjuvants along with antibiotics has been advocated in multiple clinical studies in the past. Hyaluronic acid, due to its multi-functional role has emerged as a potential adjuvant along with SRP to help improve the clinical parameters in re-gaining periodontal health.

The periodontal wound healing comprises sequence of reproducible & firmly controlled biological actions, including inflammation, epithelium formation, granulation tissue formation & tissue remodeling. During the inflammatory phase, it forms a structural framework by interacting with fibrin clot and helps to prevent pathogen colonization by directly preventing microbial proliferation. In the granulation phase, HA stimulates proliferation of cells, movement of matrix cells into granulation tissue matrix. The fragments formed due to HA also helps to boost the development of blood vessels (angiogenesis) in wound sites. Furthermore, Hyaluronic acid speeds up rejuvenation of bone by proliferation, chemotaxis and isolation of mesenchymal cells.

4. Conclusion

It is evident from the various clinical studies that local application of HA has a multifactorial function in the treatment of chronic periodontitis and even after post-periodontal surgery for the repair and regeneration of periodontal tissues and alveolar bone. Due to its versatile nature and exceptional physicochemical properties, HA has been used in various forms and concentrations and has reported favorable clinical outcomes as seen in different clinical studies which further confirm HA's beneficial effects in wound healing and tissue regeneration.

5. Source of Funding

None.

6. Conflict of Interest

None.

7. Acknowledge

We acknowledge IntelliMed Healthcare Solutions LLP, Mumbai, India, for medical writing support.


References

- Ialenti A, Rosa D. Hyaluronic acid modulates acute and chronic inflammation. *Agents Actions*. 1994;43(1-2):44–51.
- Dahiya P, Kamal R. Hyaluronic Acid: a boon in periodontal therapy. *N Am J Med Sci*. 2013;5(5):309–24.
- Oksala O, Salo T, Tammi R, Häkkinen L, Jalkanen M, Inki P. Expression of proteoglycans and hyaluronan during wound healing. *J Histochem Cytochem*. 1995;43(2):125–60.
- Laurent TC, Fraser JR. Hyaluronan. *FASEB J*. 1992;6(7):2397–404.
- Pirnazar P, Wolinsky L, Nachnani S, Haake S, Pilloni A, Bernard GW. Bacteriostatic effects of hyaluronic acid. *J Periodontol*. 1999;70(4):370–4.
- Weigel PH, Fuller GM, Leboeuf RD. A model for the role of hyaluronic acid and fibrin in the early events during the inflammatory response and wound healing. *J Theor Biol*. 1986;119(2):219–53.
- Abatangelo G, Martelli M, Vecchia P. Healing of hyaluronic acid-enriched wounds: histological observations. *J Surg Res*. 1983;35(5):410–6.
- King SR, Hickerson WL, Proctor KG. Beneficial actions of exogenous hyaluronic acid on wound healing. *Surgery*. 1991;109(1):76–84.
- Laurent TC, Laurent UB, Fraser JR. Functions of hyaluronan in wound repair. *Wound Rep Regen*. 1995;5(5):429–61.
- Jentsch H, Pomowski R, Kundt G, Göcke R. Treatment of gingivitis with hyaluronan. *J Clin Periodontol*. 2003;30(2):159–64.
- Embery G, Oliver WM, Stanbury JB, Purvis JA. The electrophoretic detection of acidic glycosaminoglycans in human gingival sulcus fluid. *Arch Oral Biol*. 1982;27(2):177–86.
- Pogrel MA, Lowe MA, Stern R. Hyaluronan (hyaluronic acid) in human saliva. *Arch Oral Biol*. 1996;41(7):667–71.
- Boeriu CG, Springer J, Kooy FK, Broek LD, Eggink G. Production Methods for Hyaluronan. *Int J Carbohydrate Chem*. 2013;(624967):1–14. doi:10.1155/2013/624967.
- Rodríguez-Marquez CD, Arteaga-Marin S, Sánchez AR, Hernández RA, Castro-Muñoz R. A Review on Current Strategies for Extraction and Purification of Hyaluronic Acid. *Int J Mol Sci*. 2022;23(11):6038. doi:10.3390/ijms23116038.
- Marques HK, Pravda M, Wolfova L, Velebny V, Schaaf P, Vrana NE. Hyaluronic Acid and Its Derivatives in Coating and Delivery Systems: Applications in Tissue Engineering, Regenerative Medicine and Immunomodulation. *Adv Healthc Mater*. 2016;5(22):2841–55.
- Volpi N, Schiller J, Stern R. Role, Metabolism, Chemical Modifications and Applications of Hyaluronan. *Curr Med Chem*. 1998;16(1):41–6.
- Balogh L, Polyak A, Mathe D, Kiraly R, Thuroczky J, Terez M. Absorption, uptake and tissue affinity of high-molecular-weight hyaluronan after oral administration in rats and dogs. *J Agric Food Chem*. 2008;56(22):10582–93.
- Sutherland IW. Novel and established applications of microbial polysaccharides. *Trends Biotechnol*. 1998;16(1):41–6.
- Waddington RJ, Moseley R, Embery G. Reactive oxygen species: a potential role in the pathogenesis of periodontal diseases. *Oral Dis*. 2000;6(3):138–51.
- Chen WY, Abatangelo G. Functions of hyaluronan in wound repair. *Wound Repair Regen*. 1999;7(2):79–89.
- Moseley R, Waddington RJ, Embery G. Hyaluronan and its potential role in periodontal healing. *Dent Update*. 2002;29(3):144–52.
- Håkansson L, Hällgren R, Venge P. Regulation of granulocyte function by hyaluronic acid. In vitro and in vivo effects on phagocytosis, locomotion, and metabolism. *J Clin Invest*. 1980;66(2):298–305.
- Wisniewski HG, Vilcek J. TSG-6: an IL-1/TNF-inducible protein with anti-inflammatory activity. *Cytokine Growth Factor Rev*. 1997;8(2):143–56.
- Larjava H, Heino J, Kähäri VM, Krusius T, Vuorio E. Characterization of one phenotype of human periodontal granulation-tissue fibroblasts. *J Dent Res*. 1989;68(1):20–5.
- Pm B, Rc P. The effect of chronic inflammation on gingival connective tissue proteoglycans and hyaluronic acid. *J Oral Pathol*. 1986;15(7):67–47. Available from: <https://pubmed.ncbi.nlm.nih.gov/3098943/>.
- Bartold PM, Page RC. The effect of chronic inflammation on gingival connective tissue proteoglycans and hyaluronic acid. *J Oral Pathol*. 1986;15(7):367–74.
- Ruggiero SL, Bertolami CN, Bronson RE, Damiani PJ. Hyaluronidase activity of rabbit skin wound granulation tissue fibroblasts. *J Dent Res*. 1987;66(7):1283–7.
- Mendes RM, Silva G, Lima MF, Calliari MV, Almeida AP, Alves JB. Sodium hyaluronate accelerates the healing process in tooth sockets of rats. *Arch Oral Biol*. 2008;53(12):1155–62.
- Deed R, Rooney P, Kumar P, Norton JD, Smith J, Freemont AJ. Early-response gene signalling is induced by angiogenic oligosaccharides of hyaluronan in endothelial cells. Inhibition by non-angiogenic, high-molecular-weight hyaluronan. *Int J Cancer*. 1997;71(2):251–6.
- Jentsch H, Pomowski R, Kundt G, Göcke R. Treatment of gingivitis with hyaluronan: Gingivitis treatment with hyaluronan. *J Clin Periodontol*. 2003;30(2):159–64.
- Pistorius A, Willershausen B. The clinical application of hyaluronic acid in gingivitis therapy. *Quintessence Int*. 2005;36(7-8):531–8.
- Sahayata VN, Bhavsar NV, Brahmabhatt NA. An evaluation of 0.2% hyaluronic acid gel (Gengigel®) in the treatment of gingivitis: a clinical & microbiological study. *Oral Health Dent Manag*. 2014;13(3):779–85.
- Mesa F, Aneiros J, Cabrera A, Bravo M, Caballero T, Revelles F. Antiproliferative effect of topic hyaluronic acid gel. Study in gingival biopsies of patients with periodontal disease. *Histol histopathol*. 2002;17(3):47–53.
- Johannsen A, Tellefsen M, Wikesjö U, Johannsen G. Local delivery of hyaluronan as an adjunct to scaling and root planing in the treatment of chronic periodontitis. *J Periodontol*. 2009;80(9):1493–500.
- Polepalle T, Srinivas M, Swamy N, Aluru S, Chakrapani S, Chowdary BA. Local delivery of hyaluronan 0.8% as an adjunct to scaling and root planing in the treatment of chronic periodontitis: A clinical and microbiological study. *J Indian Soc Periodontol*. 2015;19(1):37–42.
- Gontiya G, Galgali SR. Effect of hyaluronan on periodontitis: A clinical and histological study. *J Indian Soc Periodontol*. 2012;16(2):184–92.
- Rajan P, Baramappa R, Rao NM, Pavaluri AK, Rahaman PI. Hyaluronic Acid as an Adjunct to Scaling and Root Planing in Chronic Periodontitis. A Randomized Clinical Trial. *J Clin Diagn Res*. 2014;8(12):11–5.
- Bevilacqua L, Eriani J, Serroni I, Liani G, Borelli V, Castronovo G. Effectiveness of adjunctive subgingival administration of amino acids and sodium hyaluronate gel on clinical and immunological parameters in the treatment of chronic periodontitis. *Annali di Stomatologia*. 2012;3(2):75–81.
- El-Sayed F, Dahaba KM, Aboul-Ela MA, Darhous S. Local application of hyaluronan gel in conjunction with periodontal surgery: a randomized controlled trial. *Clin Oral Invest*. 2012;16(4):1229–65.
- Bogaerde LV. Treatment of infrabony periodontal defects with esterified hyaluronic acid: clinical report of 19 consecutive lesions. *Int J Period Rest Dent*. 2009;29(3):315–38.
- Briguglio F, Briguglio E, Briguglio R, Cafiero C, Isola G. Treatment of infrabony periodontal defects using a resorbable biopolymer of hyaluronic acid: a randomized clinical trial. *Quintessence Int*. 2013;44(3):231–71.
- Pilloni A, Annibaldi S, Dominici F, Paolo D, Papa C, Cassini M. Evaluation of the efficacy of an hyaluronic acid-based biogel on periodontal clinical parameters. A randomized-controlled clinical pilot study. *Ann Stomatol*. 2012;2(3-4):3–9.
- Olszewska-Czyz I, Kralik K, Prpic J. Biomolecules in Dental Applications: Randomized, Controlled Clinical Trial Evaluating the Influence of Hyaluronic Acid Adjunctive Therapy on Clinical Parameters of Moderate Periodontitis. *Biomolecules*.

2021;11(10):1491. doi:10.3390/biom11101491.

44. Ballini A, Cantore S, Capodiferro S, Grassi FR. Esterified hyaluronic acid and autologous bone in the surgical correction of the infra-bone defects. *Int J Med Sci.* 2009;6(2):65–71.

Author biography

Kirti Shukla, Medical Advisor  <https://orcid.org/0000-0003-4304-8541>

Kranti Kiran Pebbili, Cluster Medical Head

Cite this article: Shukla K, Pebbili KK. Role of hyaluronic acid during periodontal therapy & post-periodontal surgeries. *Arch Dent Res* 2022;12(2):89-96.