



Case Report

Osteomyelitis of maxilla: A rare case report

Shallu Bansal^{1,*}, Akshay Mishra¹, Madhulika Bagde¹, Abhishekh Kumar¹

¹Dept. of Oral and Maxillofacial Surgery, Swargiya Dadasaheb Kalmegh Smruti Dental College, Nagpur, Maharashtra, India



ARTICLE INFO

Article history:

Received 05-08-2021

Accepted 25-09-2021

Available online 31-12-2021

Keywords:

Osteomyelitis

Sequestra

ABSTRACT

Treatment of this condition involves sequestrectomy and debridement of the necrosed bone and extraction of the involved teeth with antibiotic therapy and adjunct therapy.¹ Cranial bones and brain might get involved in maxillary osteomyelitis.

This is an Open Access (OA) journal, and articles are distributed under the terms of the [Creative Commons Attribution-NonCommercial-ShareAlike 4.0 License](https://creativecommons.org/licenses/by-nc-sa/4.0/), which allows others to remix, tweak, and build upon the work non-commercially, as long as appropriate credit is given and the new creations are licensed under the identical terms.

For reprints contact: reprint@ipinnovative.com

1. Introduction

Osteomyelitis is defined as the inflammation of bone, followed by infection of medullary portion, which rapidly spreads to haversian system and into the periosteum.² It was a French surgeon, Edouard Chassaignac in 1852 who described osteomyelitis.³ In 1847 Rees described osteomyelitis of maxilla.⁴

Sequestra and involucrum were the terms coined in 1764 by John Hunter. Sequestra is the pocket of dead cortical bone with abscess and involucrum is new bone formed in response to the sequestra.³ Although osteomyelitis of maxillofacial region became less common after the era of antibiotic therapy. There are many systemic diseases like diabetes mellitus, HIV, malnutrition, chemotherapeutic agents which makes the patient immunocompromised, contributing to osteomyelitis.⁴ Mainly the etiology of osteomyelitis of maxilla can be classified into traumatic, rhinogenic and odontogenic (Given by Macbeth in 1952).⁵

In uncontrolled cases of diabetes, 45.1% of maxillary osteomyelitis are reported.⁶ Osteomyelitis of mandible is more common as compared to maxilla due to collateral blood supply and thin cortical bone.

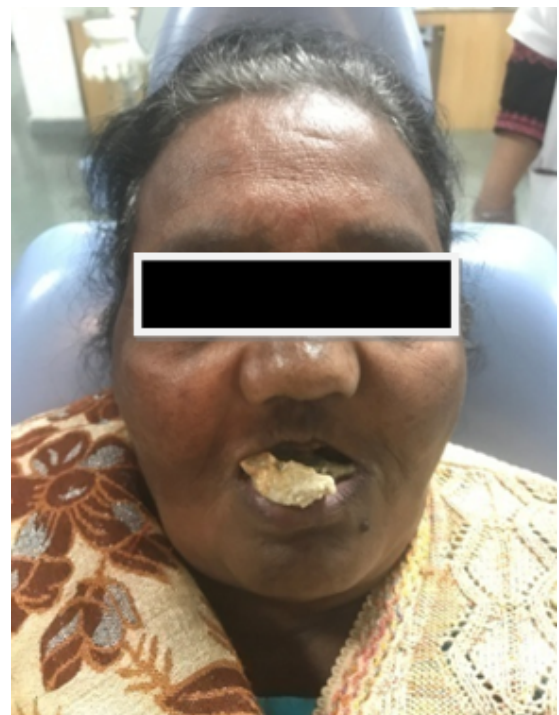

Fig. 1: Frontal view of the patient.

* Corresponding author.

E-mail address: shallu.bansal@sdk-dentalcollege.edu.in (S. Bansal).

Treatment of this condition involves sequestrectomy and debridement of the necrosed bone and extraction of the involved teeth with antibiotic therapy and adjunct therapy.¹ Cranial bones and brain might get involved in maxillary osteomyelitis. Definite diagnosis with aggressive treatment is necessary to avoid these complications.⁷ In this article we present rare case of bilateral maxillary osteotomy where 58 years old female reported with almost detached sequestrum.

2. Case Report

A 58 yrs female from Tibbi Hanuman District, reported to the Department of Oral and Maxillofacial Surgery with the chief complaint of pain and mobility in her upper right region of jaw since 4 months. Patient also complaint of difficulty in eating and drinking since 2 months. The pain was mild to moderate, intermittent in nature which aggravated on its mastication and subsided after taking medication. Patient was on self medication for approximately 2 months, when she was not totally relieved she went to local dentist. Patient was under the supervision of local dentist for two months and was referred to the Department for further treatment. General examination revealed she was conscious, cooperative and well oriented to time, place and person. Extraoral examination revealed almost detached sequestrum was present over the left maxilla (Figure 1). There was no paresthesia of bilateral infraorbital nerve. Intraoral examination revealed exposed alveolar bone from 16 to 23. On palpation sequestrum was attached to 16. Orthopantomogram confirmed the clinical diagnosis. (Figure 2) The random blood sugar was measured with glucometer was 349mg/dl. Patient was admitted in the Surendera General Hospital under Physicians' supervision and Oral and Maxillofacial Surgery Department. Physician consent was taken before the surgical procedure. Next day surgical intervention was planned under local anesthesia after. Painting and draping was done following all aseptic precautions. Local anesthesia (Lignocaine with adrenaline) (1:2,00,000) was given. Sequestrum was detached from 16 area, through irrigation was done with betadine and normal saline. Betadine ointment dipped gauze piece was given as dressing. Specimen was send for histopathological examination and it confirmed the diagnosis for osteomyelitis of maxilla. Patient stayed in the hospital for 10 days and blood sugar was monitored by sliding scale under the supervision of Physician. Regular dressing and irrigation was done. Patient was discharged on 10th day and her random blood sugar was 175mm/dl at the time of discharge. At 6 months follow up patient showed satisfactory results.

3. Discussion

Maxillofacial osteomyelitis is a rare disease, although it is very rare in the maxilla. If signs of osteomyelitis are found

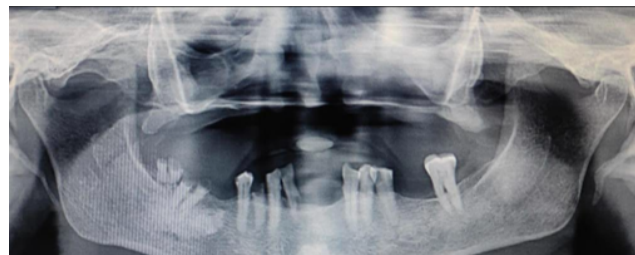


Fig. 2: Orthopantomogram (OPG)

early, treatment should be started as soon as possible. If left untreated, it will spread to other areas, reducing immunity, and the host's defense mechanism will cause the disease to spread rapidly. The most common cause of osteomyelitis is the previous pathology of the periapical tissue. Sinusitis and trauma are less common. It is a multi-microbial disease caused by many organisms. The culture and a suitable antimicrobial agent reduce the symptoms of the disease.⁸ The predisposing factors of maxillofacial osteomyelitis are tooth infection, sinusitis, trauma and radiation exposure. The two main reasons for maxillofacial osteomyelitis are tooth infections and sinusitis as per literature. Due to sinusitis, the frontal bone is most commonly affected, while the upper jaw is less affected due to poor blood supply. In this case, uncontrolled diabetes is found to be the main risk factor which is found to cause involvement of maxilla. Peravali et al. Reported 68% osteomyelitis of maxilla are because of uncontrolled diabetes. As the distribution of blood flow of jaw and weakening of immune system is seen in diabetes.^{9,10}

There are many options when examining the imaging of osteomyelitis like computed tomography (CT), magnetic resonance imaging (MRI), ultra sonography (USG). A simple panoramic X-ray of the teeth may be sufficient to diagnose this condition. However, the course of the disease can only be seen on an MRI scan, which is usually better, because the inflamed tissue produces a low-intensity signal in the normally bright bone marrow fat signal, the extent of the lesion can also be seen. This is very helpful for the follow-up treatment of the disease.¹¹⁻¹³

The pathogenesis of the disease is believed to be the relatively avascular and ischemic nature of the infected area and isolation creates areas of low oxygen and areas that are not penetrated by antibiotics. The reduced oxygen pressure reduces the bactericidal activity of polymorphic white blood cells and leads of the previous aerobic condition. The antibiotics supply in the dead bone is so slow that no matter what concentration is given, it is usually impossible to reach the target area. Even if treatment is recommended for serum levels, this may result in an ineffective antibiotic concentration at the infection site.¹⁴

Therapeutic treatment ranges from many simple non-invasive methods to more invasive radical treatments.

Non-surgical methods include antibiotics,¹⁵ non-steroidal anti-inflammatory drugs,¹⁵ hyperbaric oxygen therapy,¹⁶ bisphosphonate therapy^{17,18} depending upon the type of osteomyelitis. Surgical methods include skin removal, skin grafting, partial (marginal) resection.¹⁹ Unfortunately, conservative treatment always leads to multiple recurrences of the disease, while active treatment can lead to severe recurrence of comorbidities, and subsequent reconstruction surgery or various forms of obturators are required.²⁰ Maxillary osteomyelitis is a challenge for both clinician and patient, as it is very challenging to treat. Even though there are many advances with the diagnosis and treatment it seems to be difficult. Clinical, radiographical, histological and haematological investigation is very critical in diagnosis of osteomyelitis. Surgical excision of the involved part and adequate medicinal management provide significant success in the cases of osteomyelitis. In our case the sequestrum was almost detached and therefore no aggressive surgical intervention was needed. Hence management was possible under local anesthesia and surgical dressing (betadine dressing) were given. Secondary reconstruction was planned after one year. A through Pubmed, Medline and Google research have been done and till now none of the cases have been reported in which the sequestrum was almost detached, so this is one of the rare case itself considering that local dentist was not able to diagnose this osteomyelitis of maxilla. So we wish to conclude that careful and prompt diagnosis is important to manage these sorts of pathologies.

4. Source of Funding

None.

5. Conflict of Interest

None.

References

- Hudson JW. Osteomyelitis of the jaws: a 50-year perspective. *J Oral and Maxillofac Surg.* 1993;51(12):1294–1301. doi:10.1016/s0278-2391(10)80131-4.
- Manimaran K, Kannan PS, Kannan R. Osteomyelitis of maxilla bilateral involvement: a case report. *J Indian Acad Dent Spec.* 2011;2(2):57–8.
- Pincus DJ, Armstrong MB, Thaller SR. Osteomyelitis of the craniofacial skeleton. *Semin Plast Surg.* 2009;23(2):73–9. doi:10.1055/s-0029-1214159.
- Lumba SP, Nirola A, Grewal BS. Healed osteomyelitis of Maxilla with tooth in the floor of nose. *J Laryngol Otol.* 1971;85(8):877–9. doi:10.1017/s002221510007417x.
- Rege SR, Shah KL, Marfatia PT. Osteomyelitis of maxilla with extrusion of teeth in the floor of the nose requiring extraction. *J Laryngol Otol.* 1970;84(5):533–5. doi:10.1017/s0022215100072194.
- Jung J, Kim S, Park JS, Lee CR, Jeon JH, Kwon IJ, et al. Treatment of life-threatening acute osteomyelitis of the jaw during chemotherapy: a case report. *J Dent Anesth Pain Med.* 2020;20(4):251–9. doi:10.17245/jdapm.2020.20.4.251.
- Gupta V, Singh I, Goyal S, Kumar M, Singh A, Dwivedi G. Osteomyelitis of maxilla-A rare presentation: Case report and review of literature. *Int J Otorhinolaryngol Head Neck Surg.* 2017;3(3):771–6. doi:10.18203/issn.2454-5929.ijohns20173068.
- Huneault LM, Lussier B, Dubreuil P, Chouinard L, Désévaux C. Prevention and treatment of experimental osteomyelitis in dogs with ciprofloxacin-loaded crosslinked high amylose starch implants. *J Orthop Res.* 2004;22(6):1351–7. doi:10.1016/j.orthres.2004.04.007.
- Peravali RK, Jayade B, Joshi A, Shirganvi M, Rao CB, Gopalkrishnan K. Osteomyelitis of Maxilla in Poorly Controlled Diabetics in a Rural Indian Population. *J maxillofac oral surg.* 2012;11(1):57–66. doi:10.1007/s12663-011-0283-0.
- Koorbusch GF, Fotos P, Goll KT. Retrospective assessment of osteomyelitis: etiology, demographics, risk factors, and management in 35 cases. Oral surgery, oral medicine, oral pathology. *Oral Surg Oral Med Oral Pathol.* 1992;74(2):149–54. doi:10.1016/0030-4220(92)90373-x.
- Eckman MH, Greenfield S, Mackey WC, Wong JB, Kaplan S, Sullivan L, et al. Foot infections in diabetic patients: decision and cost-effectiveness analyses. *JAMA.* 1995;273(9):712–20.
- Piccoli BCB, Sauvain MJ, Gal I, Schibler A, Saurenmann T, Kressebuech H. Synovitis, acne, pustulosis, hyperostosis, osteitis (SAPHO) syndrome in childhood: a report of ten cases and review of the literature. *Eur J Pediatr.* 2000;159(8):594–601. doi:10.1007/s004310000500.
- Deslandre CJ, Krebs S, Kahan A. Chronic recurrent multifocal osteomyelitis: five-year outcomes in 14 pediatric cases. *Jt Bone Spine.* 2001;68(3):245–51. doi:10.1016/s1297-319x(01)00276-7.
- Eckardt JJ, Wirganowicz PZ, Mar T. An aggressive surgical approach to the management of chronic osteomyelitis. *Clin Orthop Relat Res.* 1994;298:229–39.
- Soubrier M, Dubost JJ, Ristori JM, Sauvezie B, Bussièrre JL. Pamidronate in the treatment of diffuse sclerosing osteomyelitis of the mandible. *J Oral Surg Oral Med Oral Pathol Oral Radiol Endod.* 2001;92(6):637–40. doi:10.1067/moe.2001.119739.
- Marin FG, Ortabe JJ, Reyckler H. Chronic diffuse sclerosing osteomyelitis of the mandible or mandibular location of SAPHO syndrome. *Acta Stomatol Belg.* 1996;93(2):65–71.
- Montonen M, Kalso E, Pyllkären L, Lindström BM, Lindqvist C. Disodium clodronate in the treatment of diffuse sclerosing osteomyelitis (DSO) of the mandible. *Int J oral Maxillofac Surg.* 2001;30(4):313–7. doi:10.1054/ijom.2001.0061.
- Merkesteyn JP, Groot RH, Bras J, Bakker DJ. Diffuse sclerosing osteomyelitis of the mandible: clinical radiographic and histologic findings in twenty-seven patients. *J Oral Maxillofac Surg.* 1988;46(10):825–9. doi:10.1016/0278-2391(88)90042-0.
- Suei Y, Tanimoto K, Miyauchi M, Ishikawa T. Partial resection of the mandible for the treatment of diffuse sclerosing osteomyelitis: report of four cases. *J Oral Maxillofac Surg.* 1997;55(4):410–4. doi:10.1016/s0278-2391(97)90138-5.
- Bevin CR, Inwards CY, Keller EE. Surgical management of primary chronic osteomyelitis: a long-term retrospective analysis. *J Oral Maxillofac Surg.* 2008;66(10):2073–85. doi:10.1016/j.joms.2008.06.029.

Author biography

Shallu Bansal, HOD & Professor

Akshay Mishra, Reader

Madhulika Bagde, Post Graduate Student

Abhishekh Kumar, Post Graduate Student

Cite this article: Bansal S, Mishra A, Bagde M, Kumar A. Osteomyelitis of maxilla: A rare case report. *Arch Dent Res* 2021;11(2):127-129.